

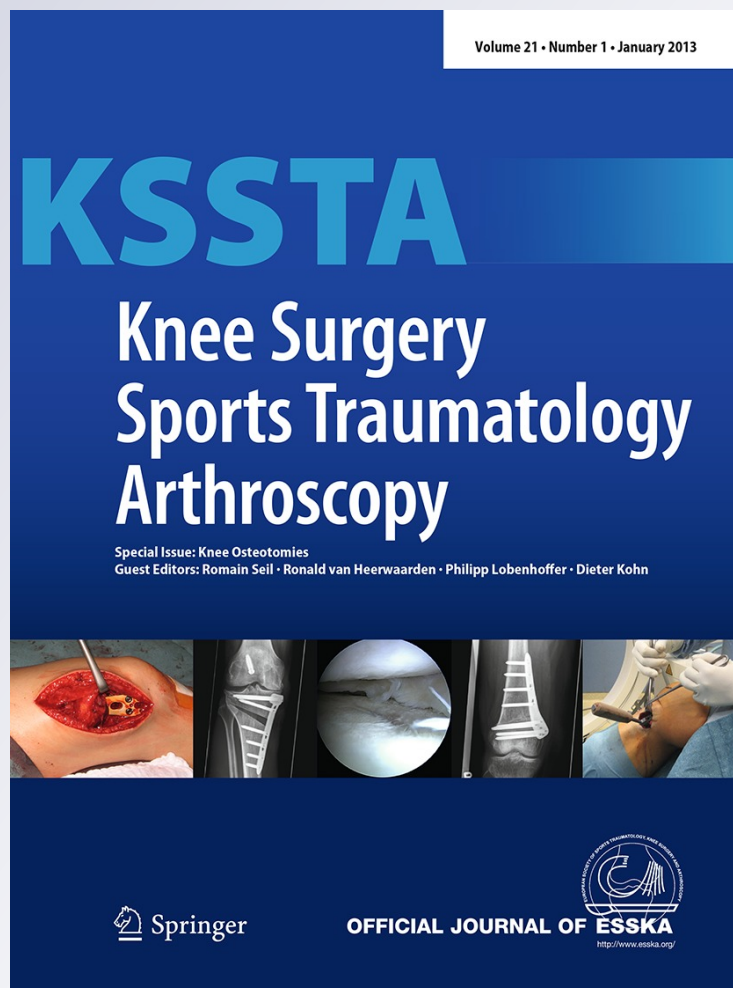
*Wedge volume and osteotomy surface  
depend on surgical technique for distal  
femoral osteotomy*

**Ronald van Heerwaarden, Michael  
Najfeld, Martijn Brinkman, Romain Seil,  
Henning Madry & Dietrich Pape**

**Knee Surgery, Sports Traumatology,  
Arthroscopy**

ISSN 0942-2056  
Volume 21  
Number 1

Knee Surg Sports Traumatol Arthrosc  
(2013) 21:206-212  
DOI 10.1007/s00167-012-2127-y



**Your article is protected by copyright and all rights are held exclusively by Springer-Verlag. This e-offprint is for personal use only and shall not be self-archived in electronic repositories. If you wish to self-archive your work, please use the accepted author's version for posting to your own website or your institution's repository. You may further deposit the accepted author's version on a funder's repository at a funder's request, provided it is not made publicly available until 12 months after publication.**

## Wedge volume and osteotomy surface depend on surgical technique for distal femoral osteotomy

Ronald van Heerwaarden · Michael Najfeld ·  
Martijn Brinkman · Romain Seil · Henning Madry ·  
Dietrich Pape

Received: 31 March 2012 / Accepted: 21 June 2012 / Published online: 6 July 2012  
© Springer-Verlag 2012

### Abstract

**Purpose** Biplanar distal femoral osteotomy (DFO) is thought to promote rapid bone healing due to the increased cancellous bone surface compared to other DFO techniques. However, precise data on the bone surface area and wedge volume resulting from both open- and closed-wedge DFO techniques remain unknown. We hypothesized that biplanar rather than uniplanar DFO better reflects the ideal geometrical requirements for bone healing, representing a large cancellous bone surface combined with a small wedge volume.

**Methods** Femoral saw bones were assigned to 4 different groups of varization distal femur osteotomies: group 1, lateral open-wedge uniplanar DFO; group 2, medial closed-wedge uniplanar DFO; group 3, lateral open-wedge

biplanar DFO; and group 4, medial closed-wedge biplanar DFO. Bone surface areas of all osteotomy planes were quantified. Wedge volumes were determined using a prism-based algorithm, applying standardized wedge heights of 5, 10 and 15 mm.

**Results** The biplanar osteotomy techniques (groups 3 and 4) created significantly larger femoral surface compared to the uniplanar groups (groups 1 and 2) ( $p = 0.036$ ). Bone surfaces after the lateral biplanar open-wedge technique (group 3) were slightly larger than the medial biplanar closed-wedge technique (group 4) and biplane techniques significantly larger than the uniplanar techniques (groups 1 and 2). Wedge volumes were significantly higher in the lateral uniplanar open-wedge (group 1) and biplanar open-wedge (group 3) techniques compared to the closed-wedge techniques (groups 2 and 4) that have nearly absent wedge volumes.

**Conclusion** Bone geometry following DFO suggests that the medial biplanar closed-wedge technique simultaneously creates smaller wedge volume and larger bone surface areas compared to the lateral biplanar open-wedge and the uniplanar DFO techniques. The horizontal cuts of the biplane DFO techniques are positioned behind the trochlear area in better healing metaphyseal bone, which further enhances bone healing potential. Although this idealized geometric view on bony geometry excludes all biological factors that influence bone healing, the current data confirm the general rule for osteotomy techniques: reducing the amount of slow gap healing and wedge volumes and simultaneously increasing the area of faster contact healing by larger bone surface areas may be beneficial for osteotomy healing.

R. van Heerwaarden (✉) · M. Brinkman  
Department of Orthopaedics Maartenskliniek Woerden,  
Limb Deformity Reconstruction Unit, Polanerbaan 2,  
3447GN Woerden, The Netherlands  
e-mail: r.vanheerwaarden@maartenskliniek.nl

M. Najfeld · R. Seil · D. Pape  
Department of Orthopaedic Surgery, Centre Hospitalier de  
Luxembourg, 1460 Luxembourg, Luxembourg

R. Seil · D. Pape  
Sports Medicine Research Laboratory, Public Research Centre  
for Health, Luxembourg, Centre Médical de la Fondation  
Norbert Metz, 76 rue d'Eich, 1460 Luxembourg, Luxembourg

H. Madry  
Department of Orthopaedic Surgery, Saarland University,  
66421 Homburg, Saarland, Germany

H. Madry  
Experimental Orthopaedics and Osteoarthritis Research,  
Saarland University, Homburg, Germany

**Keywords** Distal femur osteotomy · Bony surface ·  
Wedge volume · Surgical technique · Knee · Osteotomy ·  
Uniplanar · Biplanar · Osteoarthritis

## Introduction

Distal femur osteotomy (DFO) is a well-established method for the treatment of unicompartmental valgus gonarthrosis. Both medial closing and lateral opening techniques exist to produce a neutral to slight varus alignment [5, 11, 15]. Besides the standard uniplanar medial closing and lateral opening techniques, recently the biplanar medial closing-wedge technique has been introduced [2, 6]. Since the introduction of new rigid angle stable plates, surgical techniques have evolved, functional rehabilitation enhanced and bone healing time shortened [6, 17]. Apart from stable plate fixation, a good vascularization of the bone is mandatory for rapid bone healing. Minimally invasive lateral distal femur approaches [4] and a less invasive approach for medial closing-wedge DFO [17] preserve vascularization. However, the capacity for bone healing may vary among individuals and depends on various biological factors, which cannot be fully assessed prior to an osteotomy. In contrast, femoral geometry is quantifiable and reproducible and might influence fusion rates too.

In high tibial osteotomy (HTO), the biplanar cut was favoured over the uniplanar technique in order to increase the primary stability of the bone-implant construct. Whereas the same argument holds true for DFO, a major difference is the additional value of avoidance of the trochlear area using the biplanar technique in the distal femur [16]. Uniplane osteotomy cuts need to start and end proximal to the trochlea femoris to avoid injury to the patellofemoral joint, whereas the horizontal part of biplanar cuts can be positioned lower in better healing metaphysical bone. Differences in bone geometry between the two techniques have been neglected so far.

Bone biology suggests that the smallest possible wedge size together with the largest cancellous bone surface will promote rapid bone healing. In a previous study, wedge volumes were significantly smaller and osteotomy surface were found higher in biplanar HTO techniques [9]. The exact amount of bone surfaces created by different osteotomy techniques in the distal femur is unknown. In addition, wedge volumes resulting from the different DFO techniques have not been quantified yet.

In this study, bony surfaces and wedge volumes of both open- and closed-wedge DFOs were quantified to examine the differences in bone geometry. It was hypothesized that biplanar open- wedge and closed-wedge DFOs will create the largest amount of bone surface square millimetres and the smallest size of wedge volume compared to uniplanar osteotomy techniques.

## Materials and methods

Twenty femoral bone substitute models (Model No 1272, right femur with 10° distal femur valgus malformation;

Synbone, Malans, Switzerland) were assigned to a uniplanar (groups 1 and 2) or a biplanar (groups 3 and 4) osteotomy. The applied surgical techniques were performed in a standardized fashion according to the published guidelines [6, 11, 15]; however, for the biplanar lateral open wedge technique, until now no published guideline is available (Fig. 1a–e). All bones were mounted in a saw jig for reproducible cutting height and saw direction of horizontal descending bone cuts [1, 2]. The entry points of saw cuts were marked on the bone, and a K-wire was positioned in anteroposterior direction marking the end point of the saw cuts (in patients fluoroscopy and k-wires are used for this). Uniplanar technique saw cuts entry and end points were positioned proximal to the trochlear area whereas those of the biplanar technique were positioned 0.5 cm lower and only in the posterior 3/4 of the femur. All biplanar osteotomies consisted of an ascending cut in the horizontal plane parallel to the posterior femoral edge and at 90° angle to the horizontal cut [6]. In groups 1 and 3 open-wedge and in groups 2 and 4 closed-wedge techniques were performed. Differences between surgical techniques among the four groups are summarized in Table 1.

Bony surfaces of the horizontal part of the osteotomy were labelled A (proximal) and B (distal); frontal surfaces, if present, were labelled C (ventral) and D (dorsal, Fig. 2a).

With the aid of computer-based image analysis, images of all osteotomy planes were acquired. The measurement procedure is described in a previous manuscript in greater detail [9]. For calculation of accuracy, the one-sample t test was applied. *p* value for accuracy was 0.168, demonstrating no difference between the sample mean and the specific value. Test–retest reliability was assessed by calculation of Pearson correlation coefficient (*r*). A 10-day test–retest reliability experiment for each osteotomy plane confirmed a high reliability between time point one and two with *p* < 0.01 and *r* = 0.90 demonstrating a strong correlation.

To estimate the approximate wedge volume, the formula for prism volume calculation was used:

$$\text{wedge volume} = \text{prism volume} \times 0.5$$

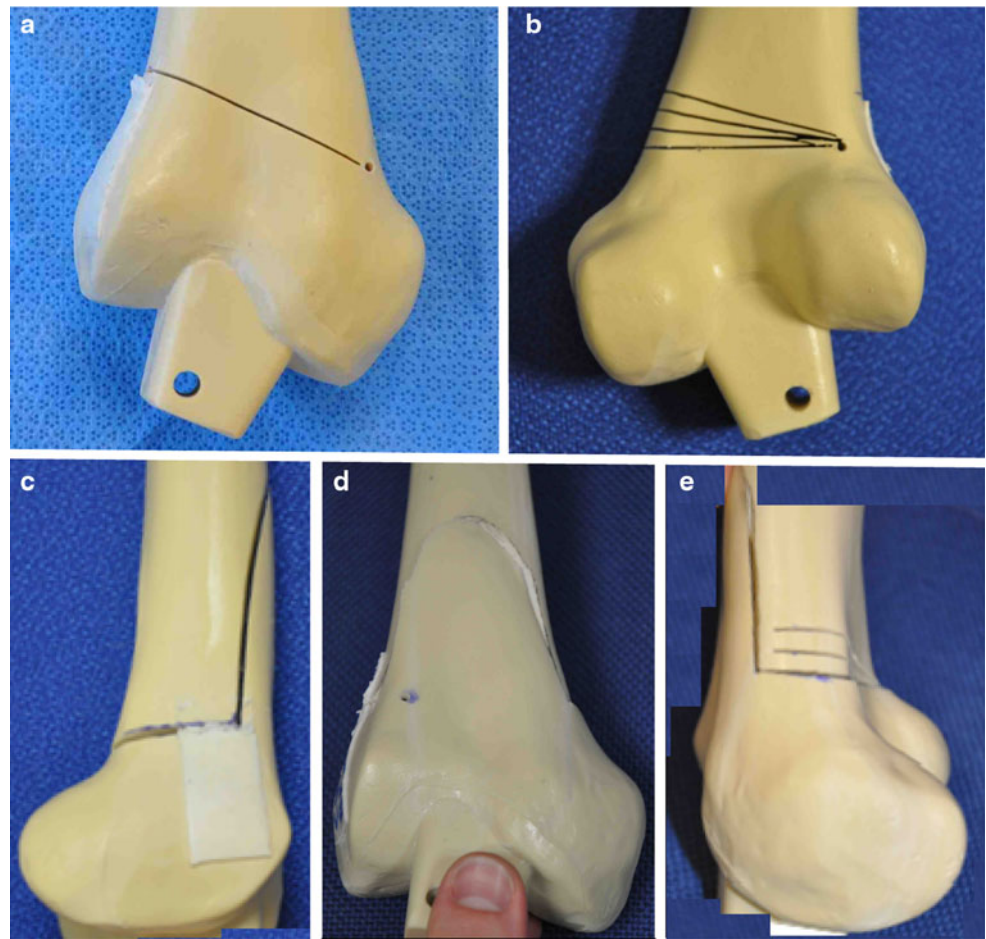
$$\text{wedge volume} = (\text{bone surfaces A} + \text{B}) \times \text{wedge height} \times 0.5$$

This calculation served as an approximation to quantify the per cent differences in wedge volume between the four distinct osteotomy types. Based on clinical relevance, wedge heights of 5, 10 and 15 mm were chosen for volume calculation in all specimens (Fig. 3).

## Statistical analysis

Based on an a priori power analysis (power 80 %, significance level 5 %), the statistical analysis was based on the

**Fig. 1** Twenty bone substitute models were assigned to a uniplanar lateral open-wedge DFO (**a**, anterior view before opening), a uniplanar medial closed-wedge DFO (**b**, dorsal view including saw cuts for different wedge heights), a lateral biplanar open-wedge DFO (**c**, lateral view before opening) or a biplane medial closing-wedge DFO (**d**, anterior view after closure of 5 mm wedge height), (**e**, medial view after closure of 5 mm wedge height)



data obtained from 5 individual samples per group. For statistical analysis, a two-way repeated measure analysis of variance (ANOVA) was used to compare surface square millimetres ( $\text{mm}^2$ ) and calculated wedge volumes ( $\text{mm}^3$ ) between groups. Differences were considered significant at  $p < 0.05$ .

## Results

### Surfaces of the different femoral planes

According to the applied standard surgical technique, a 0.8-mm-thick saw blade was used for all horizontal bone cuts. Therefore, the corresponding femoral planes were not fully congruent after the osteotomy cuts were established. No significant differences were found between the size of the distal and proximal horizontal planes (plane A and B) within and between uniplanar and biplanar groups (Fig. 2b). A nonsignificant trend towards larger frontal osteotomy planes of the biplanar OW group (group 3) compared to the biplanar closing-wedge group (group 4) was found. Finally, the summation of femoral surface

square millimetres showed no significant difference within the uniplanar and the biplanar group. However, a significant higher femoral surface was found in the biplanar groups (groups 3 and 4) compared to the uniplanar groups (groups 1 and 2) (ANOVA,  $p = 0.036$ , Fig. 2b).

The mean surface area of the opposing horizontal saw planes was found largest in the single-plane open-wedge technique. A decrease in the proximal saw cut surface (A) as well as in the dorsal biplanar contact area (D) of both the single-plane and biplanar closed-wedge techniques were related to an increase in the wedge correction as the proximal saw cut is positioned more proximal with increasing wedge heights (Fig. 1b, e). The femoral surface of the biplanar saw cut is larger in the open-wedge technique due to the more proximal location of the starting point of the biplanar saw cut relative to the joint line. With the same downslope obliquity, the end point of the cut needs to be positioned more proximal than in the medial closed-wedge technique as the medial condyle is higher than the lateral femoral condyle. As, in both techniques, biplanar saw cuts are made at  $90^\circ$  angle to the horizontal saw cut, the length differs depending on the amount of femur antecurvature.

**Table 1** Anatomical landmarks used to standardize the applied osteotomy techniques for femoral varization

Study groups	Group 1 lateral open wedge	Group 2 medial closed wedge	Group 3 lateral closed wedge	Group 4 medial closed wedge
Surgical differences with regard to	Uniplanar	Uniplanar	Biplanar	Biplanar
Relation of horizontal cut to trochlea	Proximal	Proximal	Behind	Behind
Horizontal plane osteotomy				
Starting point	Lateral cortex 5.5 cm above the joint line	Medial cortex 6 cm above the joint line	Lateral cortex 5 cm above the joint line	Medial cortex 5.5 cm above the joint line
End point	5 cm above the medial joint line 5 mm shy of the opposite cortex	5 cm above the lateral joint line 5 mm shy of the opposite cortex	4.5 cm above the medial joint line 5 mm shy of the opposite cortex	4.5 cm above the lateral joint line 5 mm shy of the opposite cortex
Direction	Slightly oblique and descending	Slightly oblique and descending	Slightly oblique and descending	Slightly oblique and descending
Frontal plane osteotomy				
Starting point			¼ dorsal to anterior femur	¼ dorsal to anterior femur
End point			Opposite cortex transection	Opposite cortex transection
Direction			Ascending: 90° angle in relation to horizontal cut	Ascending: 90° angle in relation to horizontal cut

Wedge volumes resulting from the different osteotomy techniques

The ratio of the wedge volumes resulting from the different techniques remained constant among the three wedge heights that were chosen. The wedge volumes in the uniplanar open-wedge osteotomies were higher than in the biplanar technique, and no differences were found between the closed-wedge techniques (Figs. 3, 4).

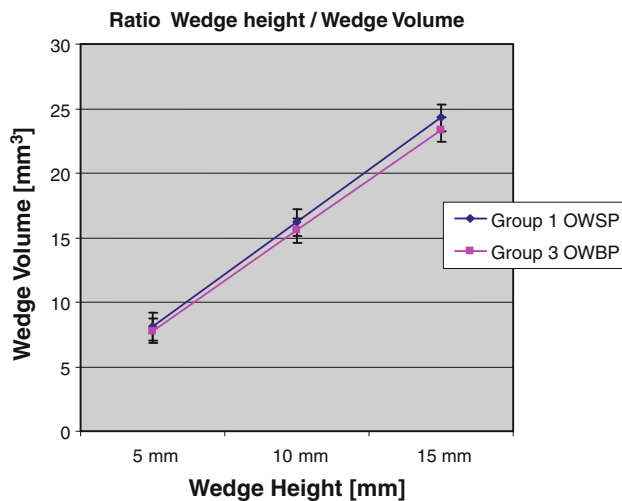
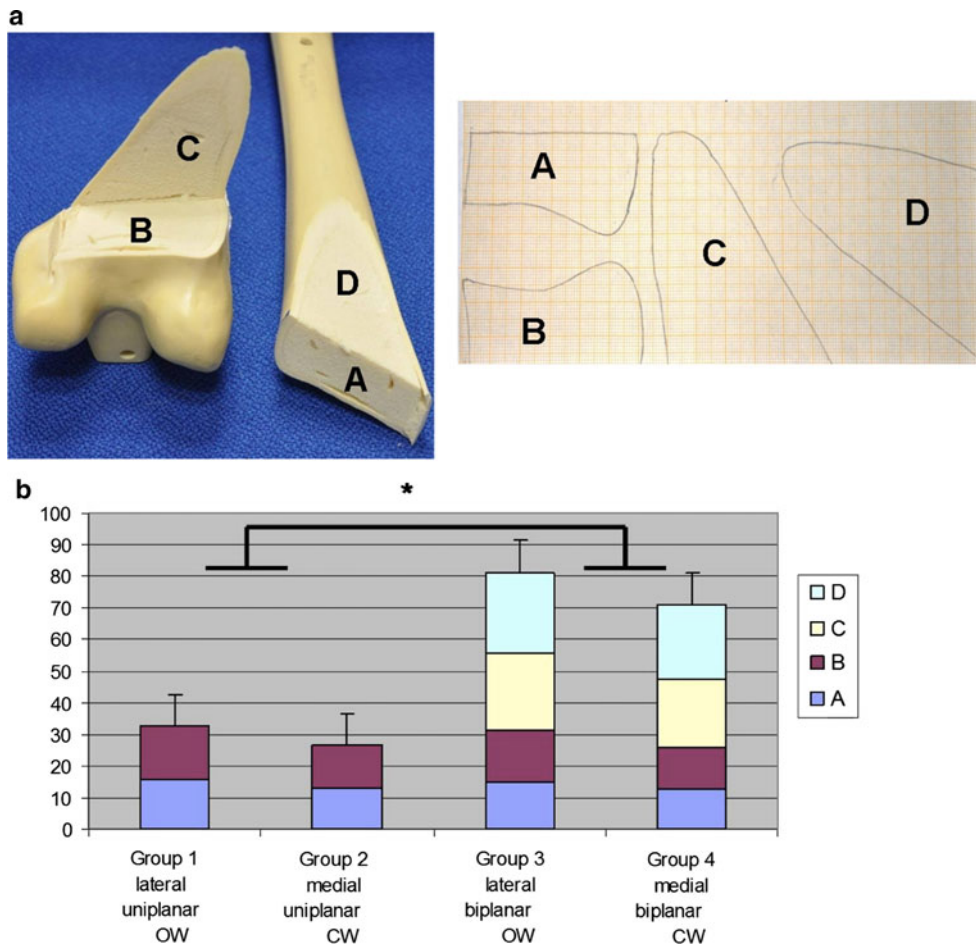
**Discussion**

The most important finding of the present study was that a biplanar medial closed-wedge DFO rather than medial uniplanar closed-wedge and lateral open-wedge techniques creates an ideal geometrical environment for bone healing. This technique combines a large area of bone-to-bone contact with a small wedge volume to be filled with repair tissue. The horizontal cuts of biplanar osteotomies are positioned closer to the joint in better healing metaphysical bone whereas the osteotomy cuts need to be positioned more proximal in the uniplanar techniques avoiding the femoral trochlea.

Contact healing that takes place in closed-wedge osteotomies and at the ascending cut of biplanar techniques progresses much faster than gap healing in open-wedge osteotomy techniques in high tibial osteotomies fixed with angle stable implants [10, 12–14]. Similar bone healing time differences can be expected to take place in distal femoral osteotomies fixed with angle stable implants; however, as yet no radiological and histological studies have been performed to evaluate bone healing in DFO. In clinical studies, uneventful bone healing at normal bone healing rate has been reported in single-plane as well as biplanar medial closed-wedge osteotomies fixed with Tomofix implants [6, 15]. In single-plane lateral open-wedge osteotomies fixed with the same angle stable implants delayed bone healing and nonunions have been described previously [7, 8].

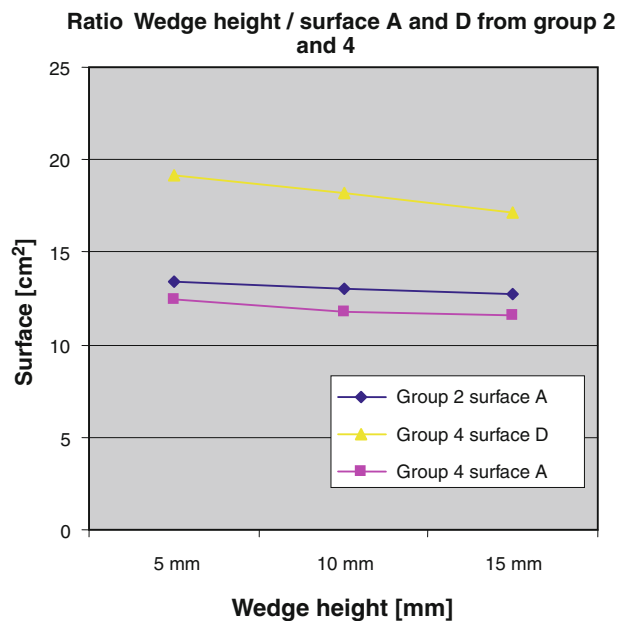
Pape et al. [9] using the same measurement protocol to measure wedge volume and osteotomy surface in high tibial osteotomies were the first to describe the consequences of different osteotomy techniques on bone healing potential. The biplanar open-wedge HTO techniques analysed paired smaller wedge volumes with larger bone surface areas as compared to a uniplanar technique similar to the lateral distal femur techniques evaluated in the present study. They concluded that reducing the amount of slow gap healing, which takes place in open-wedge osteotomies, and simultaneously increasing the area of faster contact healing will be beneficial for osteotomy healing. In this respect, a biplanar closed-wedge technique presents a

**Fig. 2 a** Surfaces following a lateral open-wedge and medial closed-wedge osteotomy in single and biplanar fashion. In all saw bones, the osteotomy planes have been labelled as follows: *A* (proximal) and *B* (distal); frontal surfaces, if present, were labelled *C* (ventral) and *D* (dorsal). Surfaces were determined by encircling bone margins on a calliper paper which covered the osteotomy planes. In specimen with a uniplanar osteotomy (*groups 1* and *2*), frontal surfaces do not exist. **b** Summation of femoral surface square centimetre (cm<sup>2</sup>) stratified by anatomical location of the different osteotomy planes. Labelling of osteotomy planes: see legend **a**



**Fig. 3** Ratio between wedge height (5, 10 and 15 mm) and calculated wedge volume (mm<sup>3</sup>) for open-wedge DFO techniques according to the formula for prism calculation

favourable situation compared to the uniplanar technique although both osteotomies have minimal wedge volumes after compression over the osteotomy.



**Fig. 4** Ratio between wedge height (5, 10 and 15 mm) and calculated surface (cm<sup>2</sup>) for closed-wedge uniplanar (*group 2*) and biplanar (*group 4*) DFO techniques

The biplanar medial closed-wedge technique was found to have superior axial stability as compared to the uniplanar technique in biomechanical tests of replicate sawbones fixed with Tomofix implants [2, 3]. Based on these results and clinical observations, adaptations of the rehabilitation protocol to early full weight bearing after 2 weeks with a hinged brace reducing torsional loading are now evaluated. Brinkman et al. [2] suggested that the increased construct stability may be caused by the large bone contact area in the biplanar technique. The present study quantifies the significant difference in bone contact areas between both techniques; however, it needs to be proven whether bone healing is enhanced in the distal femur equal to bone healing in biplanar HTO [13, 14].

A limitation of this study is the technique of calculating the wedge volumes based on a geometrical idealization, rather than measuring it as previously reported [9]. Furthermore, although a systematic error is inherent to the formula for prism volume calculation, the comparison of wedge height and wedge volume ratio was felt to be adequate to show differences between techniques.

In clinical practice, a biplanar rather than a uniplanar osteotomy should be performed for distal femoral osteotomy. A medial closing-wedge technique is favoured over a lateral opening-wedge technique due to faster bone healing potential.

## Conclusion

Bone geometry suggests that the biplanar medial closed-wedge technique simultaneously creates smallest wedge volume and larger bone surface areas compared to the uniplanar closed-wedge technique and the lateral open wedge techniques. The horizontal cuts of the biplane DFO techniques are positioned behind the trochlear area in better healing metaphyseal bone, which further enhances the bone healing potential. Although this limited and idealized geometric view excludes other biological factors that influence bone healing, current data confirm the general rule for osteotomy techniques: reducing the amount of slow gap healing and wedge volumes and simultaneously increasing the area of faster contact healing by larger bone surface areas may be beneficial for osteotomy healing. The increased mechanical stability in medial closed-wedge techniques may add in choosing medial over lateral osteotomy techniques although the latter remain popular for lower risk of damaging neurovascular structures.

**Acknowledgments** We thank Lars Goebel for helpful discussions and Hans Radenborg for assistance with the sawbones preparation. Henning Madry, Dietrich Pape and Romain Seil are partners in the project 'Experimentelle und klinische Orthopädie der Großregion/Orthopédie Expérimentale et Clinique de la Grande Région' from the

Universität der Großregion/Université de la Grande Région (UGR), supported by the INTERREG IV Programme of the European Union.

## References

1. Brinkman J-M, Hurschler C, Agneskirchner JD, Freiling D, van Heerwaarden RJ (2011) Axial and torsional stability of supracondylar femur osteotomies: a biomechanical investigation of five different plate and osteotomy configurations. *Knee Surg Sports Traumatol Arthrosc* 19:579–587
2. Brinkman J-M, Hurschler C, Agneskirchner JD, Freiling D, van Heerwaarden RJ (2011) Axial and torsional stability of an improved single plane and a new biplanar osteotomy technique for supracondylar femur osteotomies. *Knee Surg Sports Traumatol Arthrosc* 19:1090–1098
3. Brinkman J-M, Hurschler C, Agneskirchner J, Lobenhoffer P, Castelein RM, van Heerwaarden RJ (2012) Biomechanical testing of distal femur osteotomy plate fixation techniques: the role of simulated physiological loading. Submitted/Accepted for publication *Injury*
4. Farouk O, Krettek C, Miclau T, Schandelmaier P, Tschernig H (1998) Effects of percutaneous and conventional plating techniques on the blood supply to the femur. *Arch Orthop Trauma Surg* 117(8):438–441
5. Freiling D, Lobenhoffer P, Staubli A, van Heerwaarden RJ (2008) Medial closed-wedge varus osteotomy of the distal femur. *Arthroskopie* 21:6–14
6. Freiling D, van Heerwaarden R, Staubli A, Lobenhoffer P (2010) The medial closed wedge osteotomy of the distal femur for the treatment of unicompartmental lateral osteoarthritis of the knee. *Oper Orthop Traumatol* 22(3):317–334
7. Jacobi M, Wahl P, Bouaicha S, Jakob RP, Gautier E (2011) Distal femoral varus osteotomy: problems associated with the lateral open-wedge technique. *Arch Orthop Trauma Surg* 131:725–728
8. Lobenhoffer P, Freiling D (2008) Development of plate fixators: current status and perspectives. In: Lobenhoffer P, van Heerwaarden RJ, Staubli AE, Jakob RP (eds) *Osteotomies around the knee*. Thieme. AO Foundation Publishing, Stuttgart, pp 263–270
9. Pape D, Dueck K, Haag M, Lorbach O, Seil R, Madry H (2012) Wedge volume and osteotomy surface depend on surgical technique for high tibial osteotomy. *Knee Surg Sports Traumatol*. doi: [10.1007/s00167-012-1913-x](https://doi.org/10.1007/s00167-012-1913-x)
10. Perren SM (2008) Fracture healing. The evolution of our understanding. *Acta Chir Orthop Traumatol Cech* 75:241–246
11. Puddu G, Cipolla M, Cerullo G, Franco V, Gianni E (2007) Osteotomies: the surgical treatment of the valgus knee. *Sports Med Arthrosc* 15:15–22
12. Schenk RK, Willenegger HR (1977) Histology of primary bone healing: modifications and limits of recovery of gaps in relation to the extent of the defect. *Unfallheilkunde* 80:155–160
13. Staubli AE (2008) Radiological examination of bone healing after open-wedge tibial osteotomy. In: Lobenhoffer P, van Heerwaarden RJ, Staubli AE, Jakob RP (eds) *Osteotomies around the knee*. Thieme. AO Foundation Publishing, Stuttgart, pp 131–146
14. Staubli AE, Jacob HA (2010) Evolution of open-wedge high-tibial osteotomy: experience with a special angular stable device for internal fixation without interposition material. *Int Orthop* 34:167–172
15. van Heerwaarden RJ, Wymenga AB, Freiling D, Lobenhoffer P (2007) Distal medial closed wedge varus femur osteotomy stabilized with the Tomofix plate fixator. *Oper Tech Orthop* 17:12–21



16. Van Heerwaarden RJ, Wymenga AB, Freiling D, Staubli AE (2008) Supracondylar varization osteotomy of the femur with plate fixation. In: Lobenhoffer P, van Heerwaarden RJ, Staubli AE, Jakob RP (eds) Osteotomies around the knee. Thieme. AO Foundation Publishing, Stuttgart, pp 147–166
17. Visser J, Brinkman J-M, Bleys RLAW, Castelein RM, van Heerwaarden RJ (2012) The safety and feasibility of a less invasive distal femur closing wedge osteotomy technique: a cadaveric dissection study of the medial aspect of the distal femur. *Knee Surg Sports Traumatol Arthrosc*. doi:[10.1007/s00167-012-2133-0](https://doi.org/10.1007/s00167-012-2133-0)