

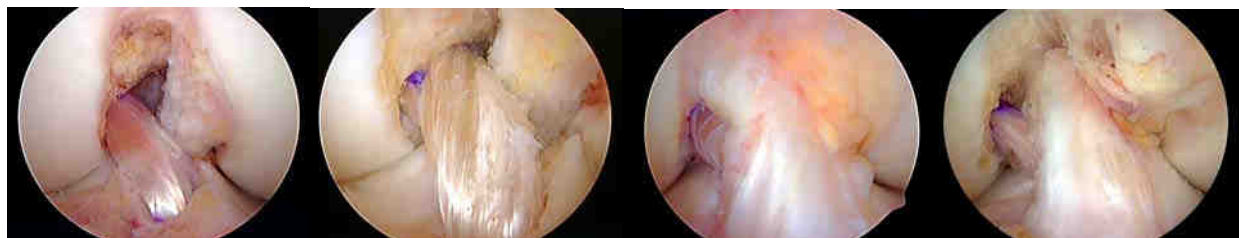## **What is Anatomic ACL Reconstruction and How Do We Achieve It?**

### **Introduction**

Over the last decade, the concept of ACL reconstruction has evolved from a surgical technique in which the goals were placement of the femoral tunnel at a location that minimized the change in length of the ACL graft (isometry) and placement of the tibial tunnel at a location that minimized the potential for roof impingement and the need for notchplasty to a surgical technique that attempts to reproduce the anatomy of the patient's native ACL. This change in concept occurred because it was recognized that placing the ACL femoral tunnel at a location that optimized graft isometry and the tibial tunnel at a location that minimized the potential for roof impingement produced a vertical ACL graft in both the sagittal and coronal planes. A vertical ACL graft may potentially resist anterior tibial translation, but often fails to resist the combined motions of anterior tibial translation and internal rotation resulting in the patient having a positive shift test after surgery.

### **The Concept of Anatomic ACL Reconstruction**

The goal of anatomic ACL reconstruction is to restore the two- bundle anatomy and function of the ACL.<sup>22,33,46,52</sup> Restoration of the two- bundle anatomy and function of the ACL does not always require the surgeon to perform a DB ACL reconstruction.<sup>22,33,46</sup> The concept and principles of anatomic ACL reconstruction can be applied to:



SB ACL

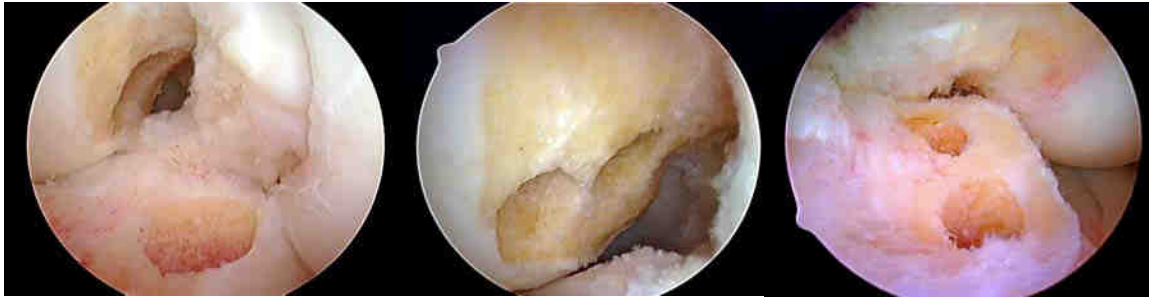DB ACL

Remnant Preservation

Augmentation

### Definition of “Anatomic” ACL Reconstruction

According to van Eck et al<sup>46</sup>, “Anatomic ACL reconstruction is defined as the functional restoration of the ACL to its native dimensions, collagen orientation and insertion sites”. From an operational perspective, an anatomic ACL reconstruction refers to a SB, DB, augmentation or tissue preserving procedure or a revision ACL reconstruction in which the bone tunnels are placed within the native ACL attachment sites.



Anatomic SB ACL reconstruction

Anatomic DB ACL reconstruction

### Principles of Anatomic ACL Reconstruction

- Restore the size, position and orientation of the native ACL attachment sites;
- Restore the 2 functional bundles of the native ACL;
- Restore the native tensioning pattern of each ACL bundle;
- Individualize the surgical procedure of each patient.<sup>22,33,46</sup>

### Individualized Surgery

Every knee is different, so every patient should not get the same operation. The surgical technique is dictated by:

- ACL injury pattern (complete ACL tear, partial ACL tear, intact remnants);
- Size of the native attachment sites (may influence graft choice and graft preparation);
- Degree of rotational instability (SB vs. DB).<sup>22,33,46</sup>

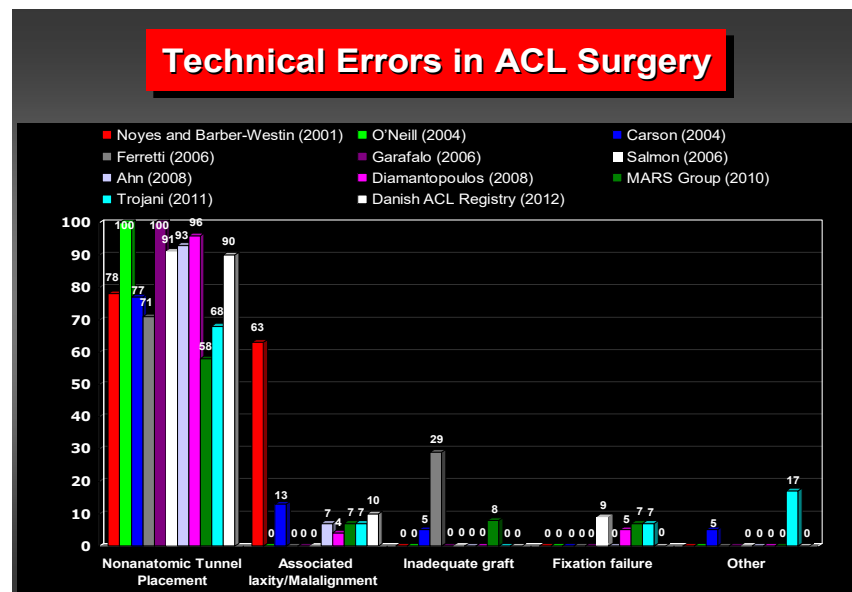
Hussein et al<sup>19</sup> have shown that when SB ACL reconstructions are individualized to the patient's native ACL attachment site size, shape and orientation, SB and DB ACL reconstructions yield similar subjective and objective results.

## Why Perform an Anatomic ACL Reconstruction?

Biomechanical, clinical and gait analysis studies have demonstrated that an anatomic ACL reconstruction better restores anterior tibial translation, rotational stability and knee kinematics compared to a non-anatomic ACL reconstruction. It is hoped, but not yet proven that by better restoring knee kinematics, anatomic ACL reconstruction techniques will improve clinical outcomes and decrease the incidence of OA after ACL reconstruction.

## Where to Place the Tunnels?

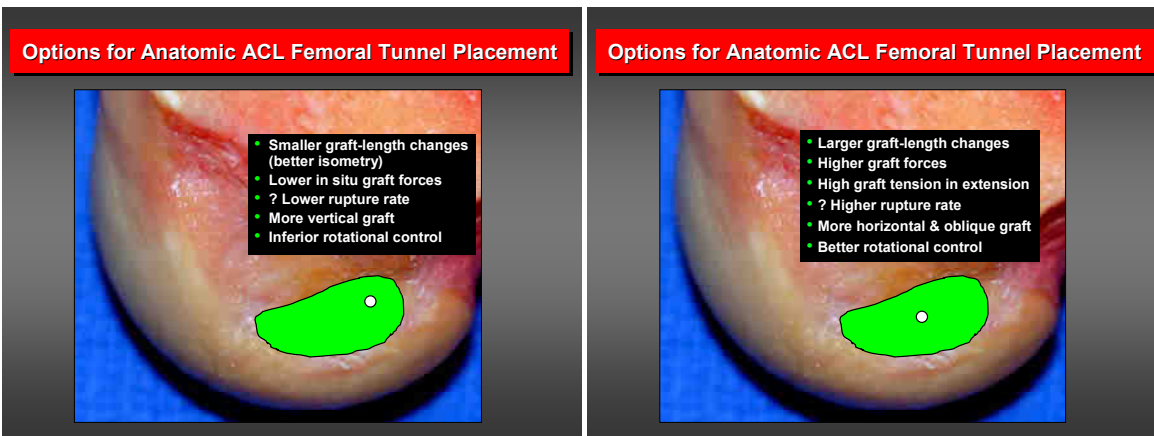
Anatomic ACL graft placement is critical to the success and clinical outcome of ACL reconstruction. Non-anatomic ACL tunnel placement is the most common technical error leading to recurrent instability and a failed ACL reconstruction.<sup>21,28,32,42,44,48,49,50</sup>



Anatomic placement of the ACL femoral tunnel is especially important because the length-tension of the ACL graft is most influenced by the position of the ACL femoral tunnel.<sup>8,14,15,16</sup> Malposition of the ACL femoral tunnel can result in excessive tightening or loosening of the ACL graft, which may result in a loss of motion and or patholaxity of the knee.<sup>8,14,15,16,21,48,49</sup> Proper placement of the femoral tunnel during ACL reconstruction is therefore a critical part of the surgical procedure. Biomechanical studies have demonstrated that center-to-center placement of a SB ACL reconstruction

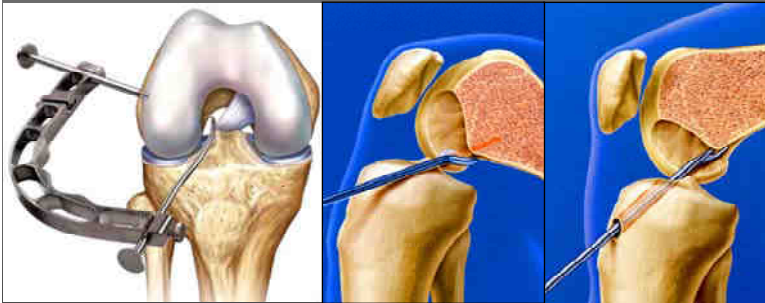
is more effective at controlling anterior tibial translation and the combined motions of anterior tibial translation and internal tibial rotation (simulated pivot shift test) and restores knee kinematics more closely to that of the normal knee compared to isometric ACL femoral tunnel placement, other anatomic ACL tunnel placements, or techniques that have traditionally restored predominantly the AM bundle fibers.<sup>3,11,24,25,26,30,34,40,51</sup> This data supports the concept that the bone tunnels for a SB ACL reconstruction should be placed at the center of the native ACL attachment sites<sup>7,18,22,24,25,26,33,46</sup>

Not all surgeons agree with concept of center-to-center placement. However, there is wide agreement that the bone tunnels should be placed within the native ACL attachment sites. Once a surgeon is able to successfully locate the ACL attachment sites, then it is a matter of choice or philosophy as to where the bone tunnels are placed within the attachment sites. Some surgeons may choose to restore more of the AM fiber region of the ACL femoral attachment site. Restoring more of the AM fibers has the potential advantages of producing an ACL graft which has smaller length changes (better isometry) and a graft which transmits less force which may result in a lower re-rupture rate. The disadvantages of this approach are that it results in a more vertically oriented graft which has inferior rotational control. Some surgeons may desire a more central graft which captures more of the PL fiber region, theoretically provides better rotational control. However, this graft placement will result in an ACL graft which experiences larger length changes and higher forces near extension. These factors could potentially result in a higher re-rupture rate.

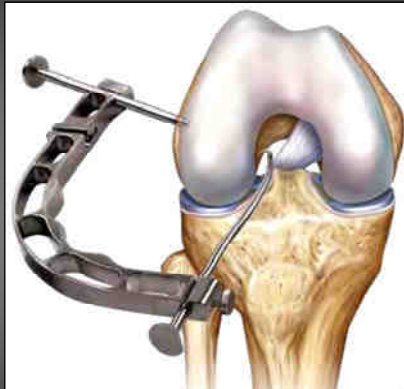


## How to Get There

### What Surgical Techniques Allow Consistent Anatomic ACL Femoral Tunnel Placement?

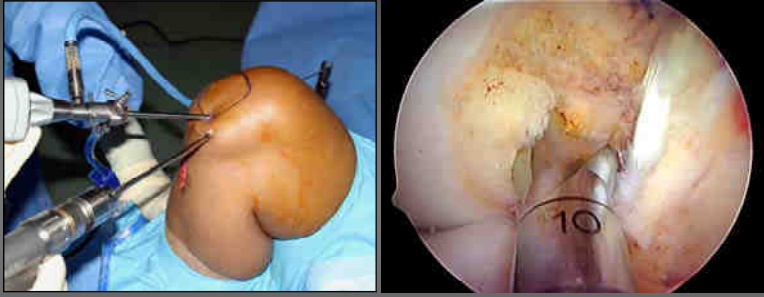

### Outside-In Drilling?



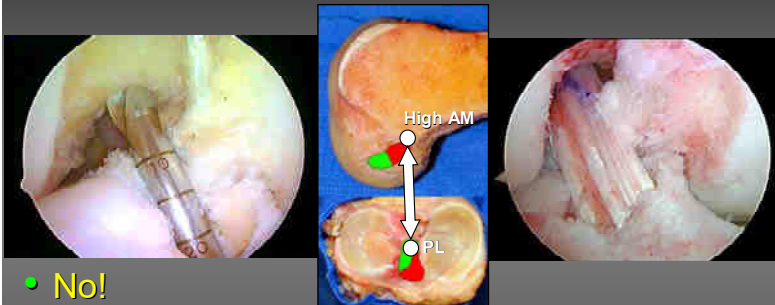
- YES!
- Independent femoral and tibial tunnels
- Longer femoral tunnel lengths more easily obtained

### Drilling through a medial portal?



- YES!
- Independent femoral and tibial tunnels
- Potential for shorter femoral tunnel lengths

### Transtibial Drilling?



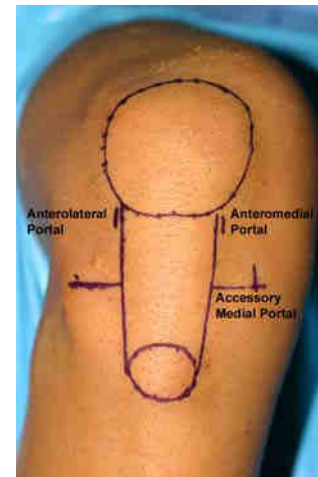
- No!
- Femoral tunnel position dependent on the tibial tunnel position
- Posterior tibial tunnel position - "High AM" femoral tunnel position = vertical ACL graft

### Portal Placement

Proper placement of the arthroscopic portals is a critical part of performing anatomic ACL surgery. Anatomic ACL femoral tunnel placement is facilitated by using three

arthroscopic portals and drilling the ACL femoral tunnel through an accessory anteromedial porta<sup>2,7,9,22,33,46</sup>l:

- The anterolateral (AL) portal - used as the primary viewing portal when performing diagnostic arthroscopy and meniscal surgery;
- The anteromedial (AM) portal - used as the primary viewing portal for identification of the ACL femoral attachment site;
- The accessory anteromedial portal (AAM) - used as a working portal to insert instrumentation into the notch and for drilling the ACL femoral tunnel.

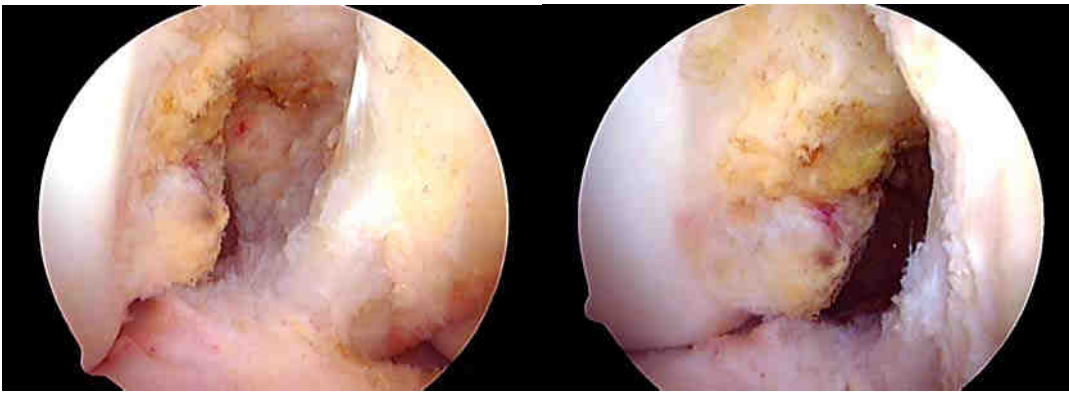

The use of three portals provides the following advantages:

- the additional medial portal allows the ACL femoral attachment site to be viewed through the AM portal, while working instrumentation is inserted into the notch through the AAM portal.
- drilling the ACL femoral tunnel through an AAM portal increases the obliquity of the ACL femoral tunnel relative to lateral wall of the notch, resulting in a longer femoral tunnel length and a more elliptical ACL femoral tunnel aperture compared to drilling the femoral tunnel through the AM portal.<sup>7,17,43</sup>

The view of the intercondylar notch and the ACL femoral attachment site changes significantly depending on the arthroscopic portal utilized. Viewing the ACL femoral attachment site through the AM portal provides an orthogonal view of the lateral wall of the notch, allowing accurate assessment of the ACL femoral tunnel position in both the shallow-deep and high-low directions. As a result, the AM portal is the preferred portal for viewing the anatomic ACL femoral attachment site. Viewing the ACL femoral attachment site through the AM portal also eliminates the need to perform a routine notchplasty for visualization purposes.



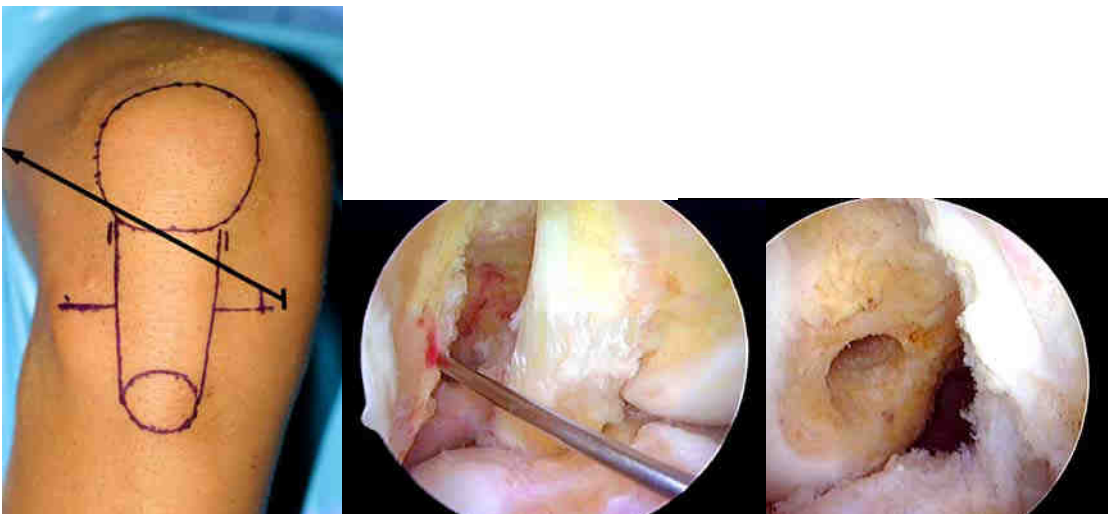


Anterolateral portal view at 90°

Anteromedial portal view at 90°

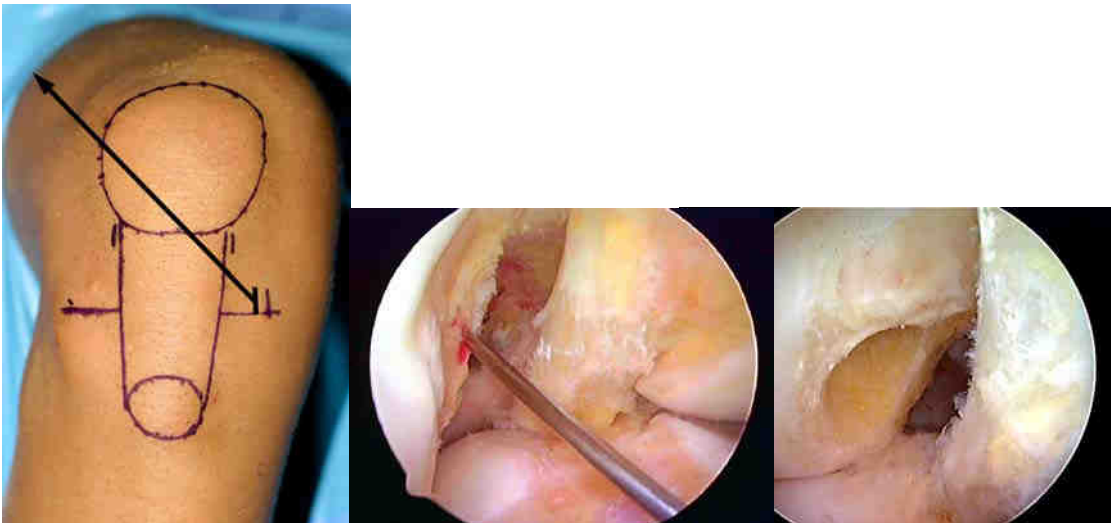
#### Establish the Accessory Anteromedial Portal

Proper placement of the AAM portal is also critical to the success of the procedure because it is the **most** important factor affecting the length of the ACL femoral tunnel.<sup>7</sup> The medial-lateral placement of the AAM portal determines both the length of the ACL femoral tunnel and the shape of the aperture of the ACL femoral tunnel.<sup>17</sup>



Positioning the AAM portal more medially results in a more perpendicular orientation of the drill bit with respect to the lateral wall of the notch and produces a shorter ACL femoral tunnel and a more circular-shaped tunnel aperture.<sup>17</sup>





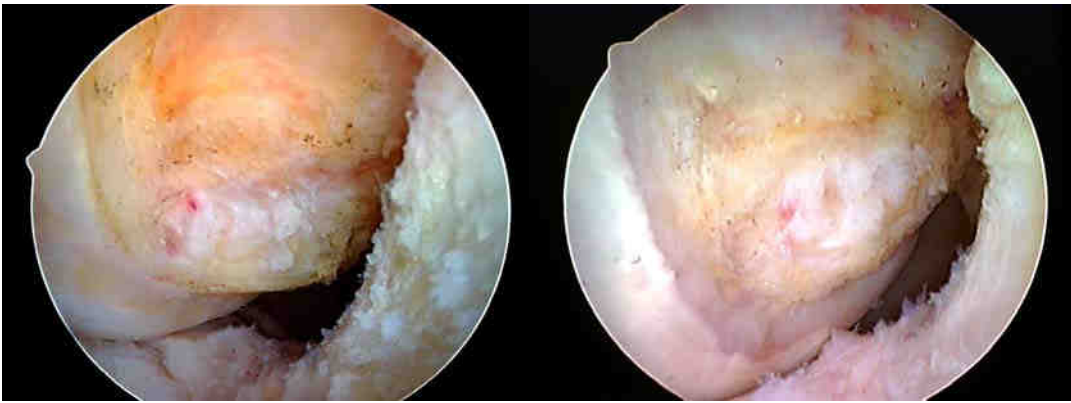Positioning the AAM portal more laterally, towards the medial border of the patellar ligament, orients the drill bit more obliquely with respect to the lateral wall of the notch and produces a longer ACL femoral tunnel length and a more elliptically-shaped tunnel aperture.<sup>17</sup>

### **Identification of the Center of the Native ACL Femoral Attachment Site**

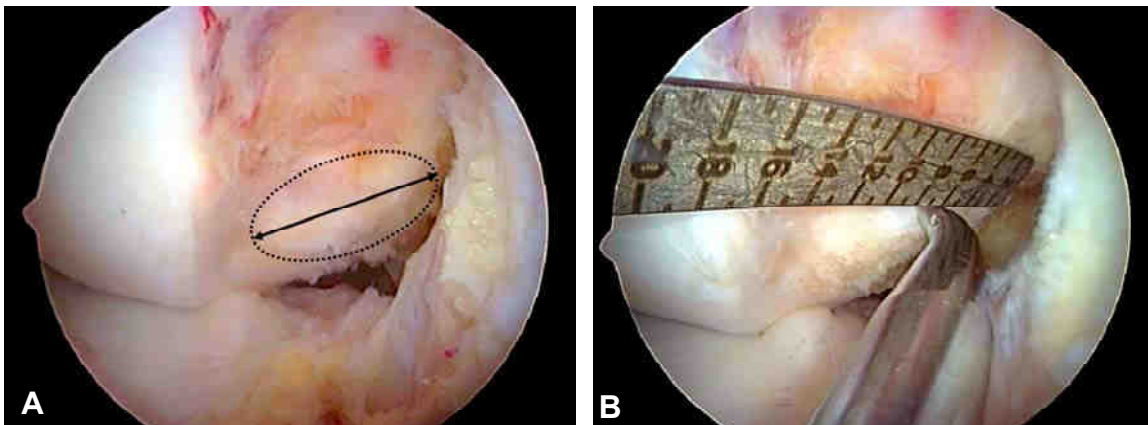
Anatomic ACL tunnel placement is best achieved by first finding the center of the native ACL attachment sites. The center of the ACL attachment sites represents a defined anatomic reference point and direction within the attachment site and attachment site locations can be specified relative to the center position. Although the clock-face reference method has often been used to specify the location of the ACL femoral tunnel, the clock-face reference method has several shortcomings: it ignores the depth of the intercondylar notch; there is no agreed upon reference position for the 3 and 9 o'clock locations; it relies on no known anatomic landmarks; and it cannot be used when viewing the ACL femoral attachment site through the AM portal.<sup>22,33,46</sup> Due to the above limitations, the clock-face reference is not an accurate method to identify or specify ACL femoral tunnel placement. ACL femoral tunnel position is more accurately located and specified using the following methods:

#### Native ACL Footprint

In most situations there are remnants of the native ACL present to aid with anatomic ACL femoral tunnel placement.



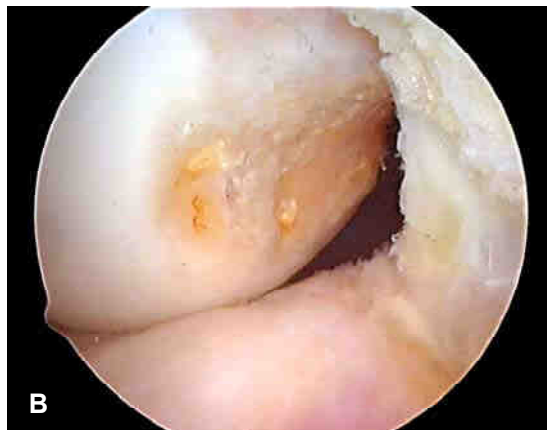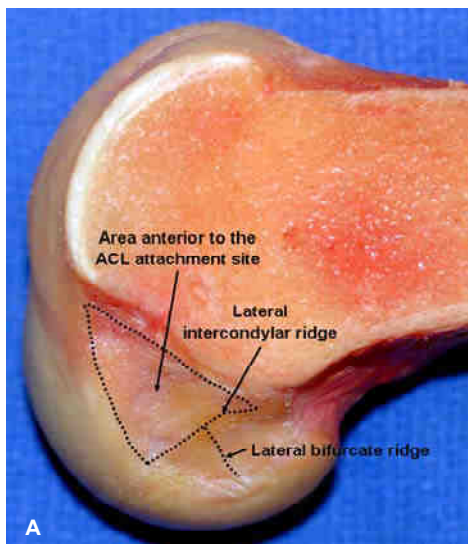
The center of the ACL femoral footprint can be estimated using the “eyeball” technique and the location marked with an angled microfracture awl. The “eyeball” technique is fairly accurate for estimating the high-low position of the tunnel. However, it should be kept in mind that due to parallax that occurs with the use of a 30 degree arthroscope, using visual cues to locate the center of the ACL femoral attachment site tends to result in the tunnel being positioned more shallow than the true center of the attachment site. The true center of the ACL attachment site can be more accurately located using an ACL ruler inserted through the AL portal and orientated along the long axis of the ACL femoral footprint.<sup>6,7</sup> The length of the ACL femoral footprint is measured from the deep (proximal) border to the shallow (distal) border along its long axis and the midpoint located and marked by inserting an angled microfracture awl through the AAM portal.



(A) AM portal view at 90° of flexion. The borders of the native ACL footprint are shown by the dotted ellipse. The knee is flexed to 110° and the length of the ACL femoral footprint is measured along its long axis (black line). (B) The ACL ruler is inserted through the AL portal and an angled microfracture awl inserted through the AAM portal. In this case, the ACL femoral footprint measures 14 mm, so the center of the footprint is placed at the 7 mm mark.

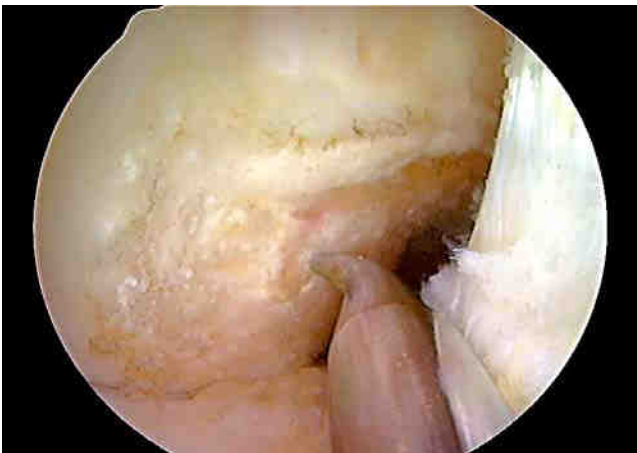
#### Lateral intercondylar and bifurcate ridges

When there are no remnants of the native ACL present, the underlying bony morphology of the ACL femoral attachment site can provide useful anatomical landmarks to assist with anatomic ACL femoral tunnel placement. The lateral intercondylar ridge, when present is an important anatomical landmark to aid the knee surgeon with anatomic ACL femoral tunnel placement since the native ACL attaches inferior to this ridge.<sup>12,27,37,39,41,47,54</sup> The lateral intercondylar ridge, therefore marks the upper limit of the superior border of the ACL femoral attachment site. In some knees it may be possible to identify a second bony ridge, the lateral bifurcate ridge which separates the attachment sites of the AM and PL bundle fibers. It is important to remember that because the cross-sectional area of the PL and AM bundles is variable from patient-to-patient, the location of the bifurcate ridge, when present, does not necessarily represent the true center of the ACL femoral attachment site.



(A) Human cadaveric knee specimen. The medial femoral condyle has been removed to show the ACL femoral attachment site. The ACL femoral attachment site is defined by the lateral intercondylar and lateral bifurcate ridges. (B) Medial portal view at 90 degrees of flexion. The lateral intercondylar ridge defines the upper border of the ACL. The ACL femoral attachment site is divided by the lateral bifurcate ridge into the attachment site areas for the AM and PL bundle fibers.

The center of the ACL femoral attachment site in the high-low direction is midway between the lateral intercondylar ridge or the superior border of the ACL footprint and the inferior articular cartilage border. According to Ziegler et al<sup>54</sup>, the center of the ACL femoral tunnel in the shallow-deep (proximal-distal) direction is 1.7 mm deep (proximal) to the lateral bifurcate ridge. When the lateral bifurcate ridge is not visualized, the shallow-deep position of the ACL femoral tunnel can be determined using an ACL ruler as described below.

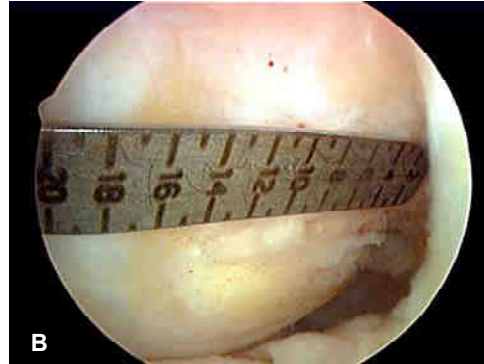
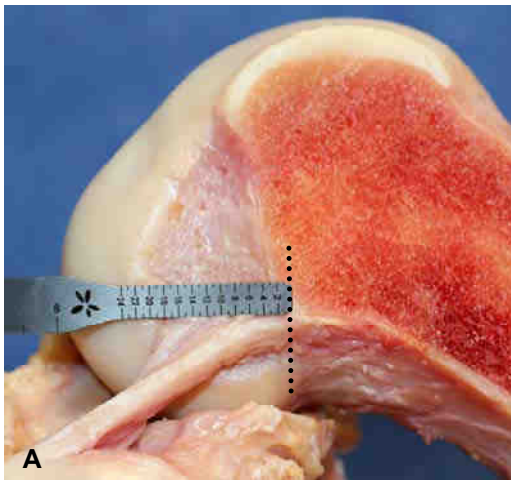


AM portal view at 90 degrees. The lateral intercondylar and bifurcate ridges are clearly seen. The tip of the angled microfracture awl is located at the center of the ACL femoral attachment site, 2 mm deep (proximal) to the lateral bifurcate ridge and midway between the lateral intercondylar ridge and the inferior (posterior) articular cartilage border.

### ACL Ruler

Use of an ACL ruler allows the surgeon to individualize the location of the ACL femoral tunnel based on the specific anatomy of the patient. This approach allows for "a la carte" or patient- specific surgery to be performed, versus the "one size fits all" approach associated with the use of offset ACL femoral aimers. This technique is particularly useful for revision ACL surgery, where there are no ACL remnants present and the bony landmarks may have been destroyed by prior notchplasty or the previous ACL femoral bone tunnel. The knee is placed at 90 degrees of flexion and the ACL femoral attachment site viewed through the AM portal using a 30 degree arthroscope. A malleable ACL ruler is bent at approximately a 45 degree angle at the 24 mm mark to allow it to lie flat along the lateral wall of the notch.<sup>6,7</sup> The ACL ruler is inserted into the intercondylar through either the AL or the AAM portal. Inserting the ruler through the AL portal allows an angled microfracture awl to be inserted through the AAM portal, allowing the surgeon to measure and simultaneously mark the ACL femoral attachment site. However, due to the height of the AL portal above the lateral joint line, in some knees it may be difficult to position the ACL ruler lower down the lateral sidewall of the notch at the location of the lateral intercondylar ridge. This limitation can often be overcome by flexing the knee to 120 degrees and or placing the knee in the figure-four position. If these maneuvers are unsuccessful, then the ruler should be inserted into the notch through the AAM portal. The lower position of the AAM portal allows the ruler to be easily positioned along the ACL femoral attachment site.

In the situation where there are no remnant fibers of the ACL present, position the lower edge of the ruler parallel to and just above the lateral intercondylar ridge. This approach allows the entire ACL femoral attachment site to be visualized which aids in determining the high-low position of the ACL femoral tunnel. Alternatively, the upper edge of the ruler can be positioned parallel to and just below the lateral intercondylar ridge. Insert the ruler along the lateral wall of the notch until the tip is positioned at the deep (proximal) border of the articular cartilage. This point represents the zero reference point for the ruler. Note that this position is different than the commonly referenced "over-the-top" position which lies higher and deeper in the notch.



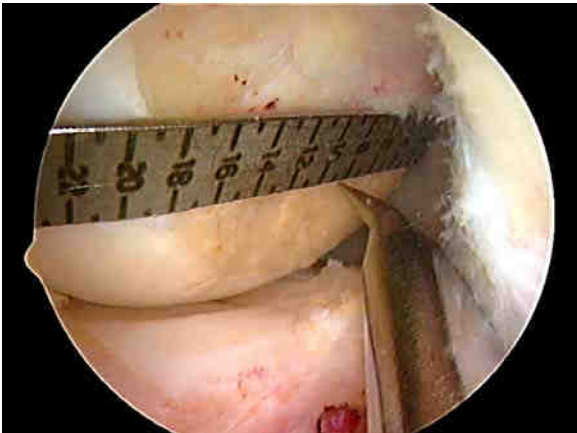
(A) Right cadaveric knee specimen. The proximal articular cartilage border is marked by the black dotted line. This represents the starting position for the ACL ruler. The lower edge of the ruler is aligned parallel to the intercondylar ridge. (B) Medial portal view right knee demonstrating the correct starting position and alignment of the ACL ruler along the lateral wall of the notch.

Mark the proximal cartilage border with an angled microfracture awl and slide the ACL ruler along the lateral wall of the notch until tip of the ruler contacts the microfracture awl. This step will accurately align the ruler at the correct starting point. The length of the side wall of the notch is measured to the point where the ACL ruler touches the shallow margin of the articular cartilage.<sup>6</sup> An angled microfracture awl is inserted into the intercondylar notch through the AAM and used to mark the location of the center of the ACL femoral attachment site. The center of the ACL femoral attachment site is located at a shallow-deep position that is 45 - 50% of the measured distance from the deep (proximal) articular cartilage border to the shallow articular cartilage border. This point has been validated by Bird et al<sup>6</sup> as a good approximation to the center of the ACL femoral attachment site. **Note** that it is important to avoid positioning the ACL femoral tunnel too shallow in the notch as this will result in an ACL graft with high graft forces in extension. To avoid this error, the zero start point of the ruler must be accurately identified and if in doubt the 50% measured distance reduced by 1 - 2 mm. The shallow-deep position of the ACL femoral tunnel can be adjusted according to the surgeon's

**Comment [T1]:** Surely the ruler in this situation is being used on the side wall. Measuring the foot print dimension is different and depends on identifying the correct fibres, that technique is mentioned earlier.

**Comment [T2]:** need to clarify how the ruler is being used - either measuring the insertion site or the sidewall of the notch

objectives. To restore more of the AM fibers, a location < 45 – 50% of the measured distance from the proximal-distal articular cartilage border is chosen.



View through the AM portal at 90° of flexion. The ACL ruler has been bent to lie flat along the lateral wall of the intercondylar notch. The ruler is inserted through the AL portal and the upper edge is positioned to lie parallel to the wall of the notch just below the lateral intercondylar ridge. The end of the ruler has been inserted to the deep (proximal) articular cartilage border which represents the zero starting point. In this case, the distance from the deep to shallow articular cartilage border measures 19 mm. The tip of the microfracture awl is positioned at the 9 mm mark which is 0.5 mm deeper than the calculated 50% distance (9.5 mm).

Anatomical studies have demonstrated that the high-low position of the center of the ACL femoral attachment site is located 7.3 – 8.6 mm above the inferior articular cartilage border.<sup>23,37,41,54</sup> This position can be achieved by positioning the tip of the microfracture awl midway between the lateral intercondylar ridge or the superior border of the ACL footprint and the inferior (posterior) articular cartilage border

#### Use of Intraoperative Fluoroscopy

At the present time, intraoperative fluoroscopy is the most accurate method to determine and evaluate ACL femoral tunnel placement.<sup>4,7,29,35</sup> Fluoroscopy gives the surgeon the ability to precisely measure and if needed change the ACL femoral tunnel position during the surgical procedure. Fluoroscopy is especially valuable in revision cases where there are usually no remnants of the native ACL present and the bony

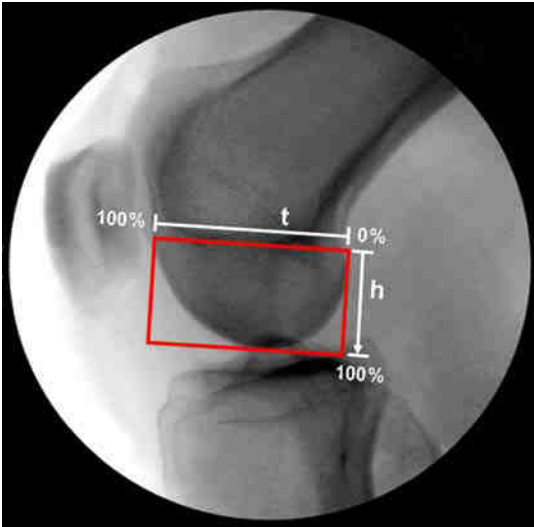


anatomy of the ACL femoral attachment site has been altered or removed by prior notchplasty and the previous ACL femoral tunnel. Fluoroscopy is also extremely helpful when attempting to preserve remnants of the torn ACL or performing an augmentation technique for a partial ACL tear. In these situations, identification of the lateral intercondylar and bifurcate ridges is not feasible as this would require resection of intact ACL fibers to expose the lateral wall of the notch. The ruler technique is also not possible since the intact ACL fibers prevent accurate positioning of the ruler along the lateral wall of the notch. Using fluoroscopy, the proper placement of the ACL femoral tunnel can be easily accomplished without the need to rely on remnants of the native ACL, measurements along the lateral wall of the notch or the bony anatomy of the ACL femoral attachment site.

The knee is positioned at 90° of flexion and an angled microfracture awl positioned at the chosen ACL femoral tunnel location. A sterile draped digital c-arm is used to take a true lateral radiograph of the knee. A true lateral radiograph is one in which the inferior (posterior) and deep (proximal) borders of the medial and lateral femoral condyles overlap. Due to the size difference between the medial and lateral femoral condyles, it is often difficult to achieve a perfect overlap of the shallow (distal) borders of both condyles. However, it is not necessary to achieve a perfect overlap of the distal condylar borders to obtain reliable information. The grid system described by Bernard and Hertel<sup>5</sup> is used to locate the center of the ACL femoral attachment site. This method is easy to use, is reproducible and has been shown to be independent of the knee size, shape, and the distance between the x-ray tube and the patient. The Bernard-Hertel grid is drawn in the following way:

1. Draw a tangent to the roof of the intercondylar notch (Blumensaat's line). Draw two lines perpendicular to that line, one at the intersection of the tangent line with the shallow border of the lateral femoral condyle and the other with the intersection of the tangent line and the deep border of the lateral femoral condyle. The lateral femoral condyle can be identified by an indentation at the distal margin (Grant's notch) and the fact that the medial femoral condyle extends more distal.

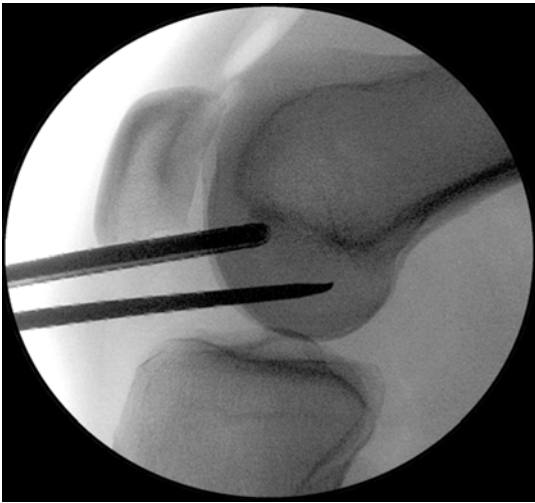2. Draw another line parallel to Blumensaat's line and tangent to the inferior border of the condyles. Measurements are made as percentages along Blumensaat's line (t), which represents the maximum sagittal diameter of the lateral femoral condyle, and line (h), which represents the maximum intercondylar notch height.



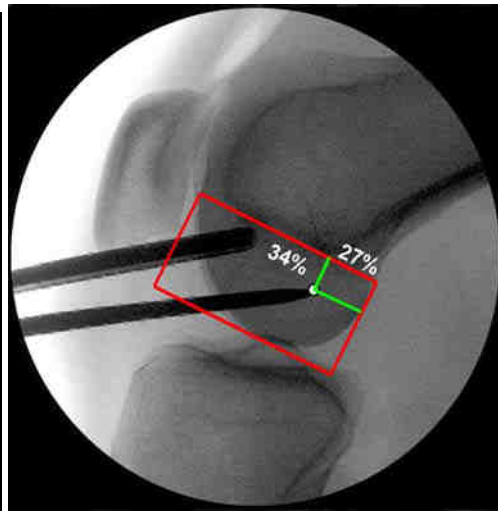
The Bernard-Hertel grid has been used to locate the centers of the PL and AM bundle in human cadaveric specimens.<sup>5,10,13,20,31,36,45,51,53</sup> A summary of these studies is shown in Table 1.

Summary of radiographic grid measurements						
Study	AMB depth	PLB depth	Av 50 % depth	AMB height	PLB height	Av 50 % height
Bernard-Hertel (1997) [45], n = 10			24.8			28.5
Yamamoto (2004) [38], n = 10	25	29	27	16	42	29
Colombet (2006) [19], n = 7	26.4	32.3	29.4	25.3	47.6	36.5
Zantop (2008) [28], n = 20	18.5	29.3	23.9	22.3	53.6	38.0
Tsukada (2008) [25], n = 36	25.9	34.8	30.4	17.8	42.1	30.0
Lorenz (2009) [50], n = 12	21	27	24	22	45	34
Forsythe (2010) [48], n = 8	21.7	35.1	28.4	33.2	55.3	44.3
Pietrini (2011) [44], n = 12	21.6	28.9	25.3	14.6	42.3	28.5
Iriuchishima (2010) [49], n = 15	15	32	23.5	26	52	39
Weighted averages	22.0	31.6	26.7	21.0	46.8	33.5

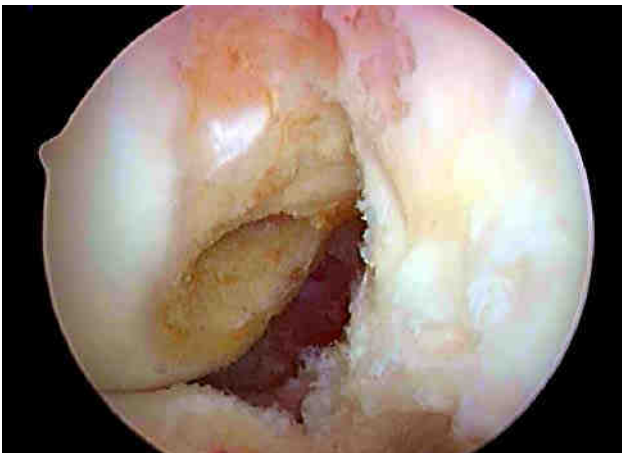
Using data from these studies, a weighted average position for the center of the ACL femoral attachment site can be calculated. This calculation reveals that the center of the ACL femoral attachment site is located at a point which is 27% along Blumensaat's line and 34% of the height of the intercondylar notch.



Fluoroscopic image



Calculation of the tunnel position

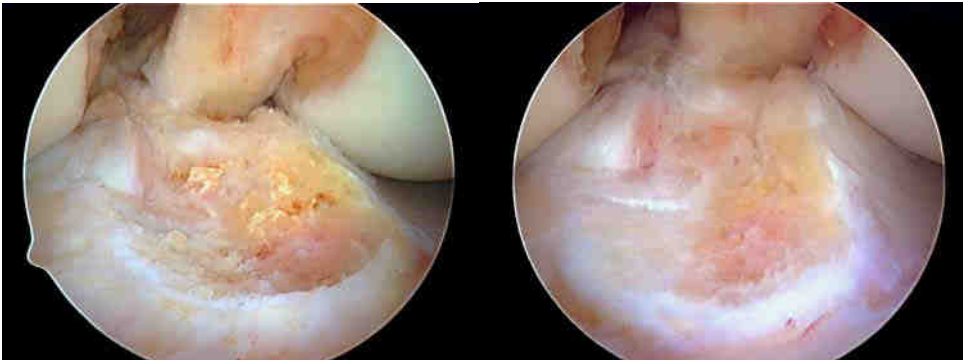

Anatomic femoral tunnel created using an ACL ruler and fluoroscopy to identify the center of the native ACL femoral attachment site. The femoral tunnel can be seen to below the lateral intercondylar ridge, in the center of the native ACL femoral attachment site.

### **Anatomic Tibial Tunnel Placement**

In anatomic ACL reconstruction, the tibial tunnel is placed in the center of the native tibial attachment site in the anterior-posterior direction and medial to the midline position in the medial-lateral direction. The ACL tibial attachment site is best by viewing through

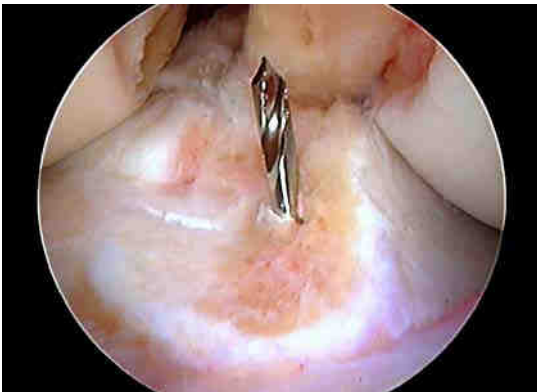
the anteromedial portal. Viewing the ACL tibial attachment site from the anteromedial portal provides a direct view as compared to the oblique view obtained by viewing through the anterolateral portal.



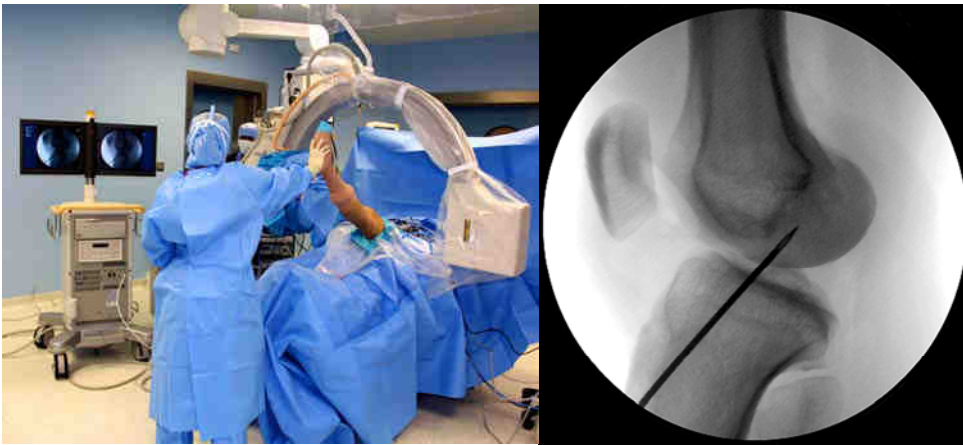
Anterolateral portal view

Anteromedial portal view

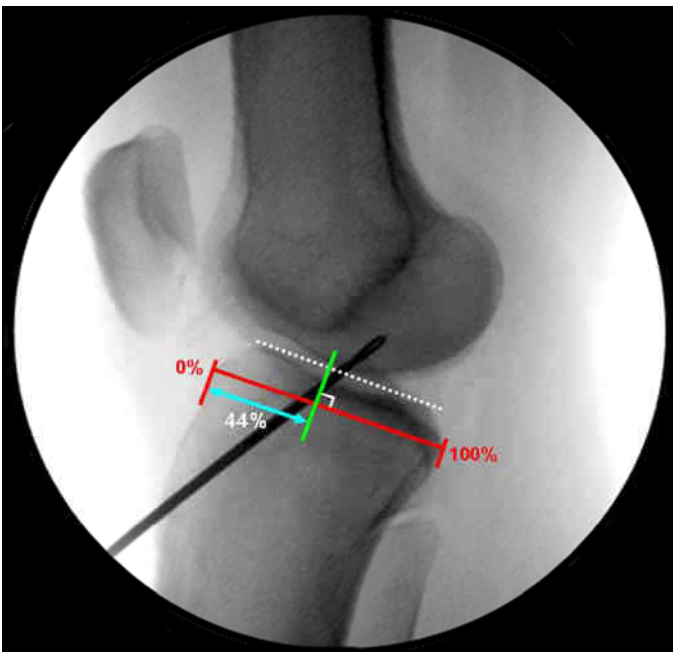The anterior-posterior position of the center of the tibial attachment site in most knees is usually 2 - 3 mm anterior to the posterior margin of the lateral meniscus and the medial-lateral position is medial to the midline distance between the medial and lateral intercondylar tubercles (spines).



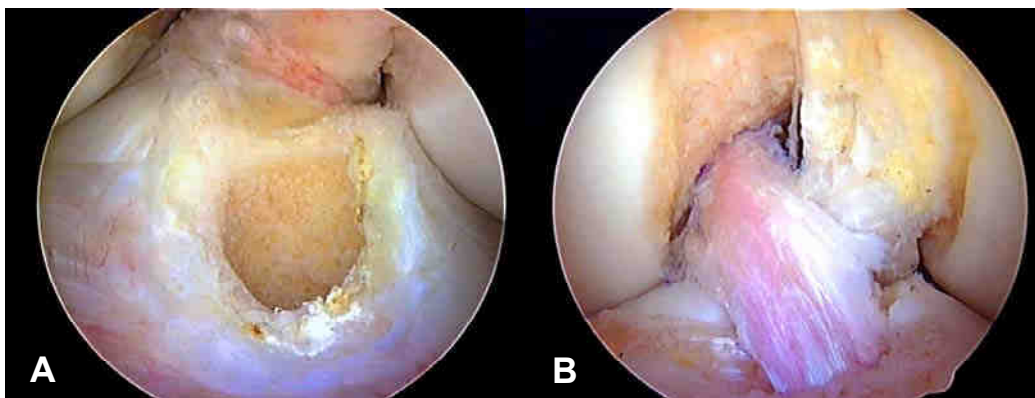
Fluoroscopy is extremely helpful to confirm anatomic placement of the tibial guide pin and to check for roof impingement.<sup>7,29,35</sup> Place the knee in maximum extension and obtain a true lateral radiographic view of the knee.



For soft tissue grafts, which will be centered along the axis of the guide pin, the tibial guide pin should lie approximately 4 - 5 mm posterior to Blumensaat's line. For bone-patellar tendon-bone grafts the tibial guide pin placement can be approximately 2 – 3 mm posterior to Blumensaat's line since the patellar tendon graft fibers are offset from the bone block and will come to lie posterior to the axis of the guide pin. The position of the tibial guide pin can be more accurately determined using the method of Amis and Jakob.<sup>1</sup> The goal is to place the tibial guide pin in the center of the ACL tibial attachment site, which has been shown to lie at 41 - 44% along the Amis-Jacob line.<sup>27</sup>



Amis-Jakob line. The medial joint line is marked by the dotted white line. The Amis-Jakob line (red line) passes through the posterior corner of the widest part of the medial tibial plateau (square posterior border) parallel to the medial joint line. The anterior tibial cortex represents 0% and the posterior tibial cortex 100% of the sagittal width of the tibia. The tibial guide pin position is calculated by dropping an orthogonal line (green line) from the point where the tibial guide pin crosses the medial joint line onto the Amis-Jakob line. The distance from the anterior tibial cortex (0%) to the orthogonal projection onto the Amis-Jakob line (blue line with arrowheads) is calculated as a percentage of the total length of the Amis-Jakob line. The tibial guide pin in this case is located at 44% along the Amis-Jakob line, which places the guide pin in the center of the ACL tibial attachment site.



(A) 10 mm anatomic tibial tunnel created using fluoroscopy to assess the tibial guide pin position. The tibial guide pin was placed at 43% of the sagittal width of the tibia. (B) Anatomic ACL reconstruction using 10 mm bone-patellar tendon-bone autograft. This graft completely restored the length of the native ACL femoral attachment and the width of the ACL tibial attachment site.

### Summary

Anatomic single-bundle (SB) ACL reconstruction refers to a SB ACL reconstruction in which the femoral and tibial bone tunnels are positioned within the native ACL attachment site. It has been proven biomechanically and clinically that anatomic ACL reconstructions better restore rotational stability compared to non-anatomic ACL

reconstructions. Anatomic ACL surgery is facilitated by using 3 portals and viewing the ACL femoral attachment site through the anteromedial portal. The clock-face reference method for locating the position of the ACL femoral tunnel has little role to play when performing anatomic ACL surgery. Identification of the center of the ACL femoral attachment site is better achieved using the following methods: identification of the native ACL footprint, identification of the lateral intercondylar and bifurcate ridges, an ACL ruler and fluoroscopy.




## References

1. Amis AA, Jakob RP (1998) Anterior cruciate ligament graft positioning, tensioning and twisting. *Knee Surg Sports Traumatol Arthrosc* 6(Suppl 1):S2-S12
2. Araujo PH, van Eck CF, Macalena JA, Fu FH (2011) Advances in the three-portal technique for single- or double-bundle ACL reconstruction. *Knee Surg Sports Traumatol Arthrosc* 19:1239-1242
3. Bedi A, Musahl V, Steuber V, Kendoff D, Choi D, Allen AA, Pearle AD, Altchek DW (2011) Transtibial versus anteromedial portal reaming in anterior cruciate ligament reconstruction: An anatomic and biomechanical evaluation of surgical technique. *Arthroscopy* 27: 380-390
4. Bernard M, Hertel P (1996) Intraoperative and postoperative insertion control of anterior cruciate ligament-plasty. A radiologic measuring method (quadrant method). *Unfallchirurg* 99: 332-340 (in German)
5. Bernard M, Hertel P, Hornung H, Cierpinski T (1997) Femoral insertion of the ACL. Radiographic quadrant method. *Am J Knee Surg* 10:14–22
6. Bird J, Carmont M, Dhillon M, Smith N, Brown C, Thompson P, Spalding T (2011) Validation of a new technique to determine mid-bundle femoral tunnel position in anterior cruciate ligament reconstruction using 3-D computed tomography analysis. *Arthroscopy* 27:1259-1267
7. Brown CH, Spalding T, Robb C (2013) Medial portal technique for single-bundle anatomical anterior cruciate ligament (ACL) reconstruction. *International Orthopaedics (SICOT)* 37:253-269
8. Bylski-Austrow DL, Grood ES, Hefsy MS (1993) Anterior cruciate ligament replacements: A mechanical study of femoral attachment location, flexion angle of tensioning, and initial tensioning. *J Ortho Res* 8:522-531
9. Cohen SB, Fu FH (2007) Three-portal technique for anterior cruciate ligament reconstruction: use of a central medial portal. *Arthroscopy* 23:325.e1-325.e4
10. Columbet P, Robinson J, Christel P, Franceschi J-P et al (2006) Morphology of anterior cruciate ligament attachments for anatomic reconstruction: a cadavric dissection and radiographic study. *Arthroscopy* 22:984-992
11. Driscoll MD, Isabell GP, Conditt MA, Ismaili BS et al (2012) Comparison of 2 femoral tunnel locations in anatomic single-bundle anterior cruciate ligament reconstruction: a biomechanical study. *Arthroscopy* 28:1481-1489
12. Ferretti M, Ekdahl M, Shen W, Fu F (2007) Osseous landmarks of the femoral attachment of the anterior cruciate ligament: An anatomic study. *Arthroscopy* 23: 1218-1225

13. Forsythe B, Kopf S, Wong AK, Martins CA-Q et al (2010) The location of femoral and tibial tunnels in anatomic double-bundle anterior cruciate ligament reconstruction analyzed by three-dimensional computed tomography models. *J Bone Joint Surg Am* 92-A:1418-1429
14. Grood ES (1992) Placement of knee ligament grafts. In Finerman GA, Noyes FR (eds) *Biology and Biomechanics of the traumatized synovial joint: The knee as a model*, American Academy of Orthopaedic Surgeons, Rosemont, Illinois
15. Hefzy MS, Grood ES (1986) Sensitivity of insertion locations on the length patterns of anterior cruciate ligament fibers. *J Biomech Eng* 108:73-82
16. Hefzy MS, Grood ES, Noyes FR (1989) Factors affecting the region of most isometric femoral attachments. Part II: anterior cruciate ligament. *Am J Sports Med* 17:208-216
17. Hensler D, Working Z, Illingworth K, Thorhauer E, Tashman S, Fu F (2011) Medial portal drilling: effects on the femoral tunnel aperture morphology during anterior cruciate ligament reconstruction. *J Bone Joint Surg Am* 93: 2063-2071
18. Hussein M, van Eck CF, Cretnik A et al (2012) Prospective randomized clinical evaluation of conventional single-bundle, anatomic single-bundle, and anatomic double-bundle anterior cruciate ligament reconstruction. 281 cases with 3- to 5-year follow-up. *Am J Sports Med* 40:512-520
19. Hussein M, van Eck CF, Cretnik A, Dinevski D, Fu FH (2012) Individualized anterior cruciate ligament surgery: a prospective study comparing anatomic single- and double-bundle reconstruction. *Am J Sport Med* 40:1781-1788
20. Iriuchishima T, Ingham SJM, Tajima G, Horaguchi T et al (2010) Evaluation of the tunnel placement in the anatomical double-bundle ACL reconstruction: a cadaver study. *Knee Surg Sports Traumatol Arthrosc* 18:1226-1231
21. Kamath GV, Redfern JC, Greis PE, Burks RT (2011) Revision anterior cruciate ligament reconstruction. *Am J Sports Med* 39:199-217
22. Karlsson J, Irrgang JJ, van Eck CF, Samuelsson K, Mejia HA, Fu FH (2011) Anatomic single- and double-bundle anterior cruciate ligament reconstruction, part 2. Clinical application of surgical technique. *Am J Sport Med* 39:2016-2026
23. Kaseta MK, DeFrate LE, Charnock BL, Sullivan RT, Garrett WE (2008) Reconstruction technique affect femoral tunnel placement in ACL reconstruction. *Clin Orthop Relat Res* 466:1467
24. Kato Y, Ingham SJM, Kramer S et al (2010) Effect of tunnel position for anatomic single-bundle ACL reconstruction on knee biomechanics in a porcine model. *Knee Surg Sports Traumatol Arthrosc* 18:2-10

25. Kato Y, Maeyama A, Lertwanich P, Wang JH et al (2013) Biomechanical comparison of different graft positions for single-bundle anterior cruciate ligament reconstruction. *Knee Surg Sports Traumatol Arthrosc* 21:816-823
26. Kondo E, Merican AM, Yasuda K, Amis AA (2011) Biomechanical comparison of anatomic double-bundle, anatomic single-bundle, and nonanatomic single-bundle anterior cruciate ligament reconstruction. *Am J Sports Med* 39:279-287
27. Kopf S, Musahl V, Tashman S, Szczodry M, Shen W, Fu FH (2009) A systematic review of the femoral origin and tibial insertion morphology of the ACL. *Knee Surg Sports Traumatol Arthrosc* 17:213-219
28. Lind M, Menhert F, Pedersen AB (2012) Incidence and outcome after revision anterior cruciate ligament reconstruction: results from the Danish registry of knee ligament reconstructions. *Am J Sports Med* 40:1551-1557
29. Lobenhoffer P, Bernard M, Agneskirchner J (2003) Quality assurance in cruciate ligament surgery. *Arthroscopie* 16: 202–208, German
30. Loh JC, Fukuda Y, Tsuda E, Steadman RJ, Fu FH, Woo SL (2003) Knee stability and graft function following anterior cruciate ligament reconstruction: comparison between the 11 o'clock and 10 o'clock femoral tunnel placement. *Arthroscopy* 19:297-304
31. Lorenz S, Elser F, Mitterer M, Obst T, Imhoff AB (2009) Radiographic evaluation of the insertion sites of the 2 functional bundles of the anterior cruciate ligament using 3-dimensional computed tomography. *Am J Sports Med* 37:2368-2376
32. Marchant B, Noyes F, Barber-Westin S, Fleckenstein C (2010) Prevalence of nonanatomical graft placement in a series of failed anterior cruciate ligament reconstruction. *Am J Sports Med* 38:1987-1996
33. Muller B, Hofbauer M, Wongcharoenwatanna J, Fu FH (2013) Indications and contraindications for double-bundle ACL reconstruction. *International Orthopaedics (SIGOT)* 37:239-246
34. Musahl V, Plakseychuk A, VanScyoc AH et al (2005) Varying femoral tunnels between the anatomical footprint and isometric positions. Effect on kinematics of the anterior cruciate ligament-reconstructed knee. *Am J Sports Med* 33:712-718
35. Passler H, Hoher J (2004) Intraoperative quality control of the placement of bone tunnels for the anterior cruciate ligament. *Unfallchirurg* 107: 263–272, in German
36. Pietrini SD, Ziegler CG, Anderson CJ, Wijdicks CA et al (2011 ) Radiographic landmarks for tunnel positioning in double-bundle ACL reconstructions. *Knee Surg Sports Traumatol Arthrosc* 19:792-800

37. Purnell ML, Larson AI, Clancy W (2008) Anterior cruciate ligament insertions on the tibia and femur and their relationships to critical bony landmarks using high-resolution volume-rendering computed tomography. *Am J Sports Med* 36:2083-2090
38. Sadoghi P, Kröpfl A, Jansson V et al (2011) Impact of tibial and femoral tunnel position on clinical results after anterior cruciate ligament reconstruction. *Arthroscopy* 27:355-364
39. Sasaki N, Ishibashi Y, Tsuda E, Yamamoto Y et al (2012) The femoral insertion of the anterior cruciate ligament: discrepancy between macroscopic and histological observations. *Arthroscopy* 28:1135-1146
40. Scopp JM, Jasper LE, Belkoff SM, Moorman CT (2004) The effect of oblique femoral tunnel placement on rotational constraint of the knee reconstructed using patellar tendon autografts. *Arthroscopy* 20:294-299
41. Shino K, Suzuki T, Iwahashi, Mae T et al (2010) The resident's ridge as an arthroscopic landmark for anatomical femoral tunnel drilling in ACL reconstruction. *Knee Surg Sports Traumatol Arthrosc* 18:1164-1168
42. Sommer C, Friederich NF, Müller W (2000) Improperly placed anterior cruciate ligament graft: correlation between radiological parameters and clinical results. *Knee Surg Sports Traumatol Arthrosc* 8:207-213
43. Tompkins M, Milewski MD, Carson EW et al (2013) Femoral tunnel length in primary anterior cruciate ligament reconstruction using an accessory medial portal. *Arthroscopy* 29:238-243
44. Trojani C, Sbihi A, Dijan P et al (2011) Causes for failure of ACL reconstruction and influence of meniscectomies after revision. *Knee Surg Sports Traumatol Arthrosc* 19:196-201
45. Tsukada H, Ishibashi Y, Tsuda E, Furaka A, Toh S (2008) Anatomical analysis of the anterior cruciate ligament femoral and tibial footprints. *J Ortho Sci* 13:122-129
46. van Eck CF, Lesniak BP, Schreiber VM, Fu FH (2010) Anatomic single- and double-bundle anterior cruciate ligament reconstruction flowchart. *Arthroscopy* 26:258-268
47. van Eck CF, Morse KR, Lesniak BP, Kropf EJ et al (2010) Does the lateral intercondylar ridge disappear in ACL deficient patients? *Knee Surg Sports Traumatol Arthrosc* 18:1184-1188
48. Wetzler MJ, Getelman MH, Friedman MJ, Bartolozzi AF (1998) Revision anterior cruciate ligament surgery: etiology of failures. *Oper Tech Sports Med* 6:64-69
49. Whitehead TS (2013) Failure of anterior cruciate ligament reconstruction. *Clin Sports Med* 32:177-20

- 
50. Wright RW, Huston LJ, Spindler KP et al (2010) Descriptive epidemiology of the multicenter ACL revision study (MARS) cohort. *Am J Sports Med* 38:1979-1986
  51. Yamamoto Y, Hsu WH, Woo SL, Van Scyoc A et al (2004) Knee stability and graft function after anterior cruciate ligament reconstruction: a comparison of a lateral and an anatomical femoral tunnel placement. *Am J Sports Med* 32:1825-1832
  52. Yasada K, van Eck CF, Hoshino Y, Fu FH, Tashman S (2011) Anatomic single- and double-bundle anterior cruciate ligament reconstruction, part 1, basic science. *Am J Sport Med* 39:1789-1799
  53. Zantop T, Wellman M, Fu FH, Peterson W (2008) Tunnel positioning of anteromedial and posterolateral bundles in anatomic anterior cruciate ligament reconstruction. Anatomic and radiographic findings. *Am J Sports Med* 36:65-72
  54. Ziegler CG, Pietrini SD, Westerhaus BD, Anderson CJ et al (2011) Arthroscopically pertinent landmarks for tunnel positioning in single-bundle and double-bundle anterior cruciate ligament reconstructions. *Am J Sports Med* 39:743-752