

ANATOMIC ACL RECONSTRUCTION

– Written by Charles Brown Jr, United Arab Emirates

INTRODUCTION

Over the last decade, reconstruction of the anterior cruciate ligament (ACL) has evolved from a surgical technique in which the objectives were ‘isometric’ femoral tunnel placement and avoidance of intercondylar notch roof impingement, towards an ‘anatomic’ surgical technique which attempts to restore the anatomy of the native ACL^{1,2}. Achieving the goals of isometric ACL graft placement and avoidance of roof impingement often resulted in the ACL femoral tunnel extending into the roof of the notch, outside of the native ACL femoral attachment site and the tibial tunnel being positioned in the posterior half of the native ACL tibial attachment site^{3,4}. Although this approach decreased roof impingement of the ACL graft and minimised the need for a notchplasty, when performed using a transtibial surgical technique it often produced a non-anatomic, vertically oriented ACL graft in both the coronal and sagittal planes^{3,4}. It should be noted that

the classic 2-incision surgical approach had previously placed the ACL femoral tunnel on the sidewall of the notch within the native ACL femoral attachment site and the tibial tunnel in the centre of the native ACL tibial attachment site⁵. Publications of the 2-incision technique reported a low failure rate (return of a positive pivot-shift test) and a low rate of revision ACL surgery⁶. Biomechanical studies have demonstrated that a vertical ACL graft may resist anterior tibial translation, but often fails to resist the combined motions of anterior tibial translation and internal tibial rotation which occur during the pivot-shift phenomenon⁷⁻¹⁴. The inability of a vertical ACL graft to resist these combined motions may result in the patient continuing to complain of symptoms of instability and continuing to experience giving-way episodes despite having an intact ACL graft. The goal of performing an anatomic ACL reconstruction is to reproduce the anatomy of the native ACL as closely as possible^{2,15}.

It has been proven biomechanically and clinically that anatomic ACL reconstructions better restore anterior tibial translation, rotational stability and normal knee kinematics compared to non-anatomic ACL reconstructions⁷⁻¹⁴. It is hoped, but not yet proven, that by restoring more normal knee kinematics, anatomic ACL reconstruction techniques will lead to better clinical outcomes as well as decrease the incidence of osteoarthritis after ACL reconstruction¹⁵.

WHAT IS ANATOMIC ACL RECONSTRUCTION?

According to van Eck et al¹⁵, ‘anatomic’ ACL reconstruction is defined as “the functional restoration of the ACL to its native dimensions, collagen orientation and insertion sites.”

- The first principle of anatomic ACL reconstruction is to reproduce as closely as possible the size, shape and location of the native ACL attachment sites^{2,15}.
- The second principle is to restore the

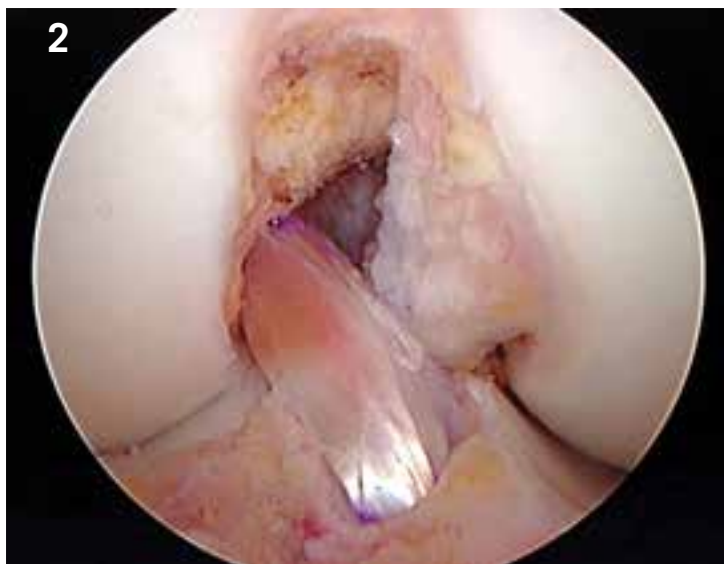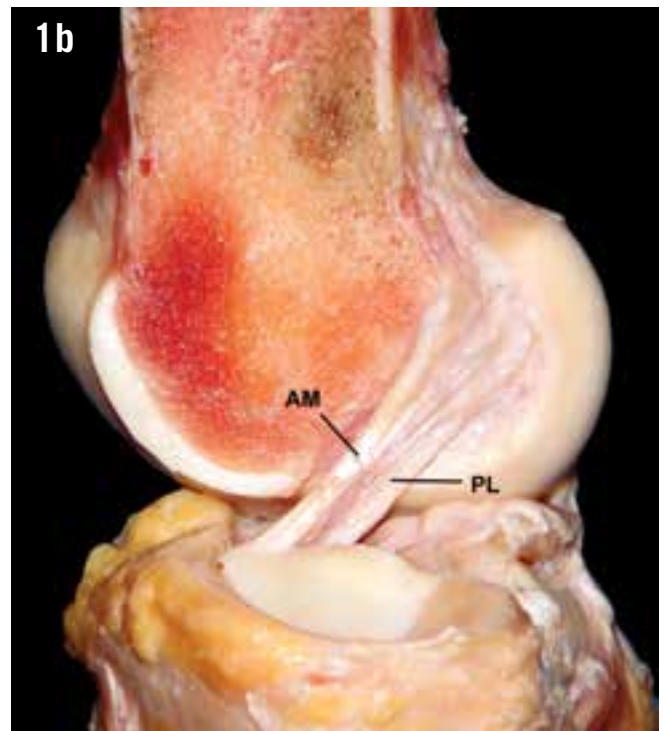
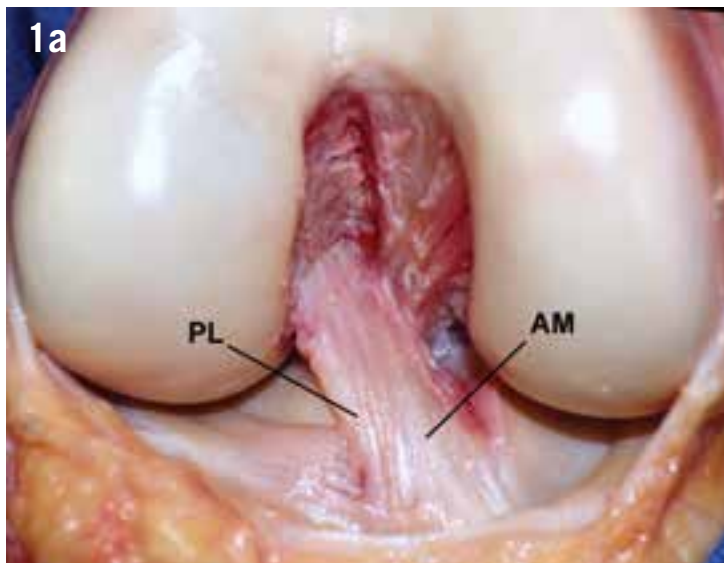


Figure 1: Right knee showing the anteromedial (AM) and posterolateral (PL) bundles. a) Frontal view. b) Lateral view.

Figure 2: Single-bundle ACL reconstruction.

two functional bundles of the ACL^{2,15} (Figure 1). In order to create an ACL replacement graft that reproduces the behaviour of the two functional bundles of the ACL, it is necessary to reproduce the size, shape and location of the native ACL attachment sites.

- The third principle is that the ACL replacement graft should reproduce the tensioning pattern of the native ACL². The anteromedial (AM) bundle fibres of the native ACL are taut throughout the range of motion, while the posterolateral (PL) bundle fibres tighten rapidly during the last 30 degrees of extension. The reconstructed ACL graft should mimic this tensioning pattern.
- The final principle of anatomic ACL reconstruction is to individualise the surgical procedure for each patient^{2,15-17}. Every patient and every knee is different,

so the same operation should not be performed in every case.

A common misconception is that anatomic ACL reconstruction implies that the surgeon must always perform a double-bundle (DB) ACL reconstruction. However, it is important to recognise that restoring the two functional bundles of the ACL does not always require the surgeon to perform a DB ACL reconstruction. Anatomic ACL reconstruction is a concept and not a specific surgical procedure. The concept of anatomic ACL reconstruction can be applied to single-bundle (SB) reconstructions (Figure 2), DB reconstructions (Figure 3), augmentation of partial ACL tears (Figure 4), ACL remnant preservation (Figure 5) and revision ACL reconstruction with an intact ACL graft (Figure 6). The specific surgical procedure should be based on the ACL injury pattern: complete ACL tear,

Every patient and every knee is different, so the same operation should not be performed in every case

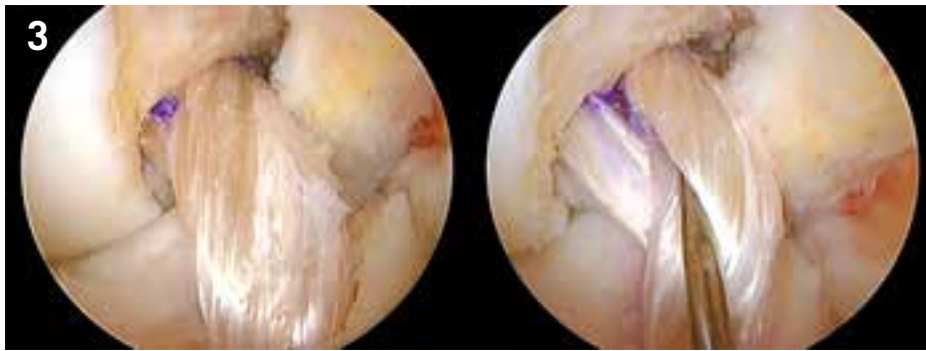


Figure 3: Double-bundle ACL reconstruction.

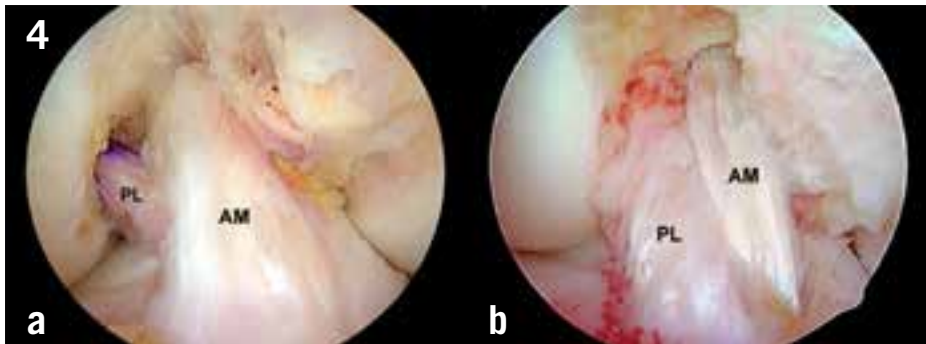


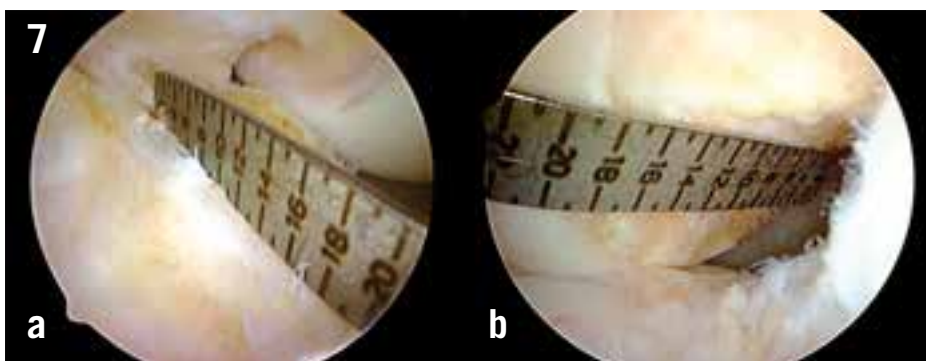
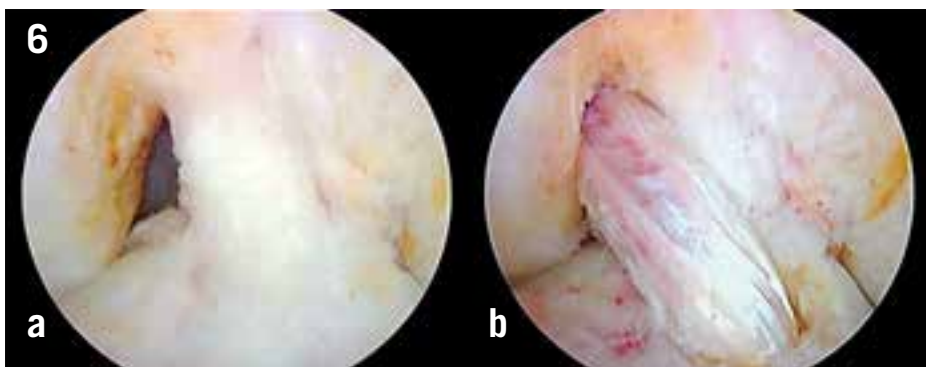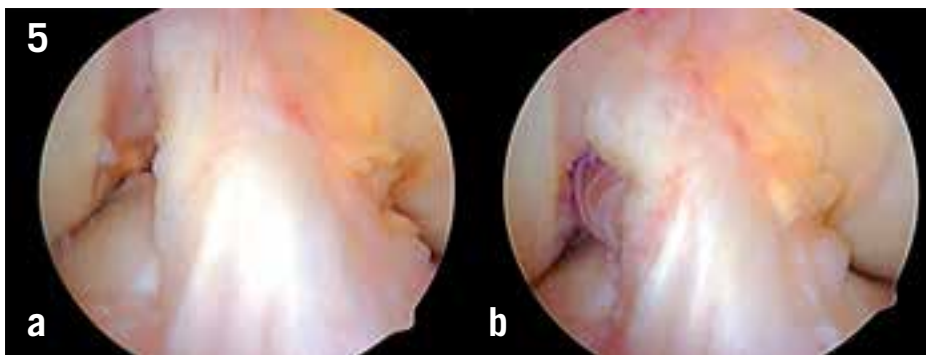
Figure 4: Augmentation techniques.

a) Isolated posterolateral (PL) bundle reconstruction. b) Isolated anteromedial (AM) bundle reconstruction.

Figure 5: a) Intact ACL remnant. b) Remnant preserving ACL reconstruction.

Figure 6: a) Intact vertical ACL reconstruction. b) Revision ACL reconstruction preserving the intact vertical ACL graft.

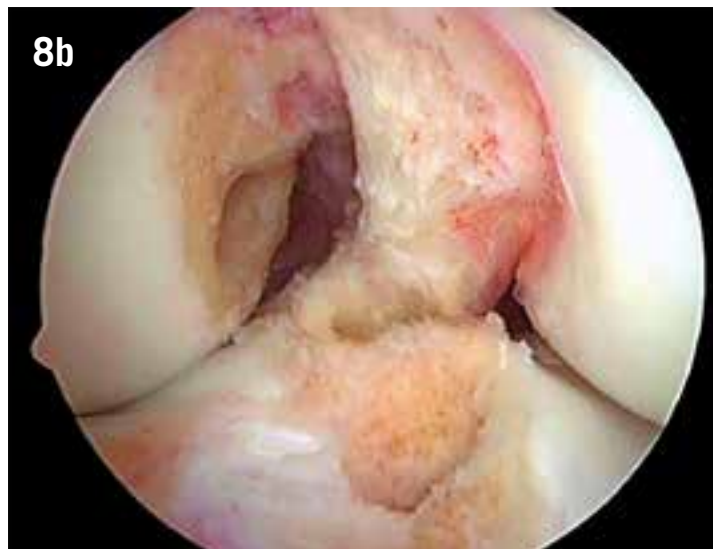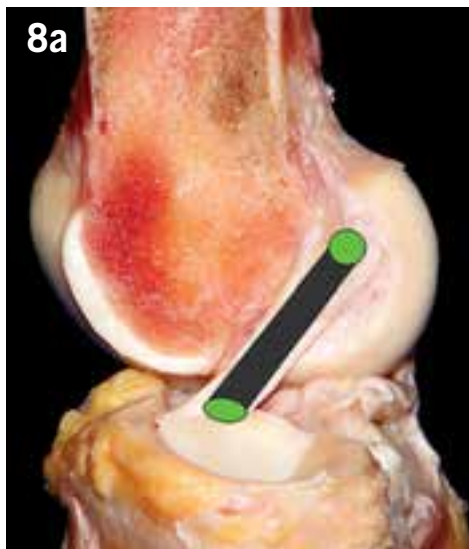
Figure 7: Malleable ACL ruler is used to measure the length of the native ACL. a) Tibial attachment site. b) Femoral attachment site.



partial ACL, intact ACL remnants, the size of the native ACL attachment sites and the degree of rotational instability. Hussein et al¹⁷ have shown that when anatomic ACL reconstructions are individualised to the size, shape and orientation of the patient's native ACL, SB and DB ACL reconstructions yield similar subjective and objective results.

RESTORATION OF THE NATIVE ACL ATTACHMENT SITES

One of the objectives of anatomic ACL reconstruction is to reproduce as closely as possible the size, shape and location of the native ACL attachment sites^{1,2,15,18,19}. During surgery, a malleable ACL ruler can be used to measure the length and width of the ACL attachment sites^{1,15,18,19} (Figure 7). These measurements can be of help to the surgeon when selecting the type of ACL replacement graft and the surgical procedure. Four-strand hamstring tendon grafts may adequately restore 12 to 14 mm long ACL attachment sites, while attachment sites that are 16 mm or longer may be better restored with larger diameter ACL graft constructs such as 5- and 6-strand hamstring tendon grafts, a bone-patellar tendon-bone graft, a quadriceps tendon graft or by performing a double-bundle ACL reconstruction¹⁹. This concept is supported by recent clinical studies that have demonstrated a higher failure rate for hamstring tendon ACL reconstructions when the diameter of the ACL replacement graft is less than 8 mm^{20,21}.



9

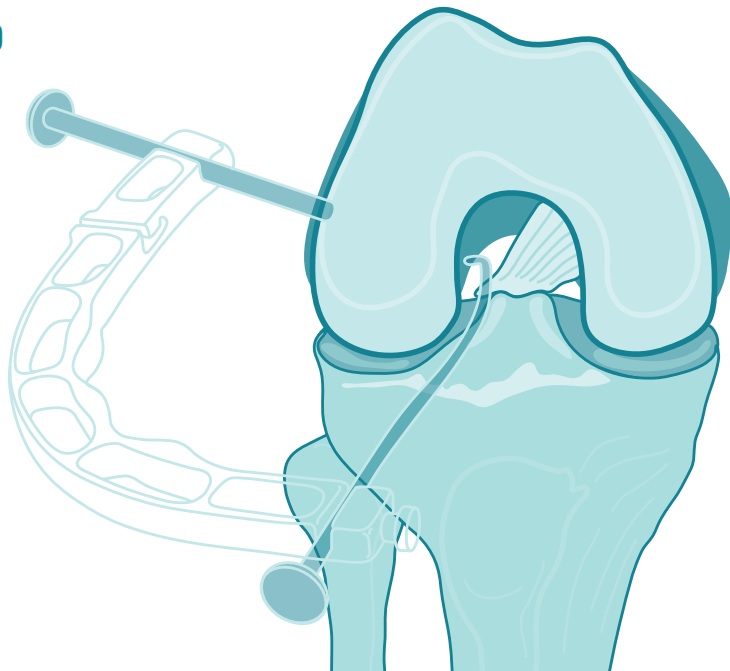


Figure 8: a) Centre-to-centre ACL graft placement. b) Femoral and tibial tunnel placement for a single-bundle ACL reconstruction. Both tunnels are placed at the centre of the native ACL attachment sites.

Figure 9: Outside-in surgical technique.

WHERE DO WE PLACE THE BONE TUNNELS FOR AN ANATOMIC ACL RECONSTRUCTION?

Operationally, an ‘anatomic’ ACL reconstruction refers to a SB, DB, ACL augmentation procedure, ACL remnant preservation or revision ACL reconstruction in which the bone tunnels are placed at the centre of the native ACL attachment sites or at the centre of the AM and PL bundle attachment sites². This article will focus on SB ACL reconstruction since this is the surgical technique performed by the majority of knee surgeons²². For SB ACL reconstruction, the bone tunnels are placed at the centre of the native ACL femoral and tibial attachment sites^{1,2,15-18} (Figure 8). This recommendation is based on biomechanical

studies which demonstrate that compared to non-anatomic PL to high-AM ACL graft placement which is often achieved using the transtibial surgical technique or other matched ACL tunnel positions located within the native ACL attachment sites, a SB ACL graft placed at the centre of the native ACL attachment sites is more effective at controlling anterior tibial translation and the pivot-shift phenomena, and more closely reproduces normal knee kinematics⁷⁻¹⁴.

WHAT SURGICAL TECHNIQUES ALLOW ANATOMIC FEMORAL TUNNEL PLACEMENT?

Two-incision technique

Arthroscopically assisted ACL reconstruction was introduced in the late 1980s

using a two-incision surgical technique⁵. In the two-incision technique, the ACL femoral tunnel is drilled from an outside-in direction through a small distal femoral incision (Figure 9). In the two-incision surgical technique, the ACL femoral tunnel position is independent of the position of the ACL tibial tunnel. With independent drilling of the ACL femoral tunnel it is possible to place the ACL femoral tunnel within the native ACL femoral attachment site 100% of the time^{23,24}. Long-term clinical studies of ACL reconstructions performed using the two-incision surgical technique have demonstrated excellent subjective and objective clinical outcomes with a low percentage of the knees having a positive pivot shift test⁶. Recognition of

10




Figure 10: Transtibial surgical technique.

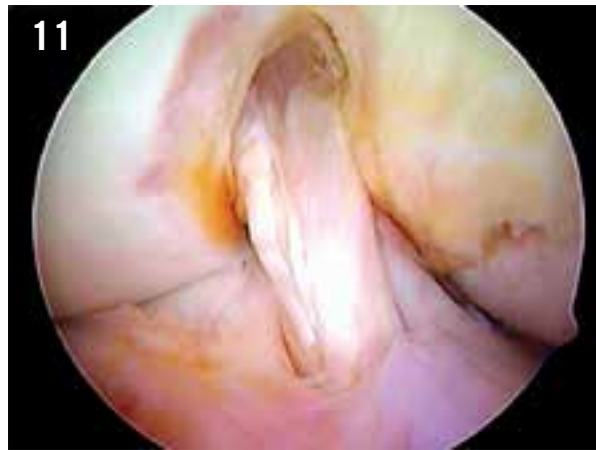

Figure 11: Non-anatomic, vertical ACL graft. The ACL graft is positioned in the posterior part of the ACL tibial attachment site and high in the roof of the intercondylar notch.

12

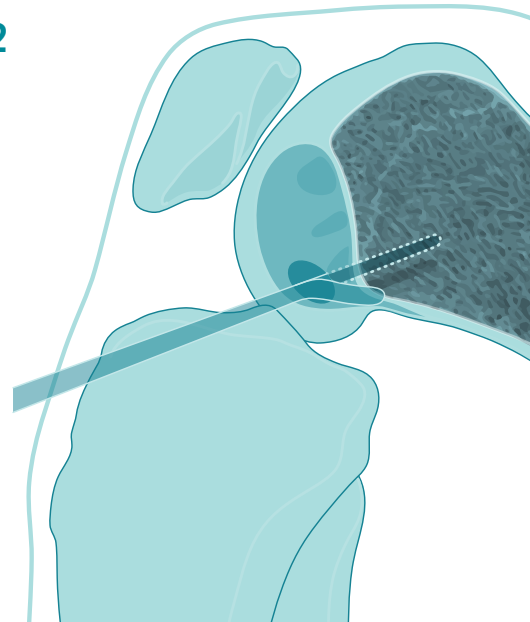


Figure 12: Anteromedial portal surgical technique.

the limitations of the transtibial surgical technique and introduction of retro reaming femoral drills has recently led to a resurgence of the two-incision surgical technique.

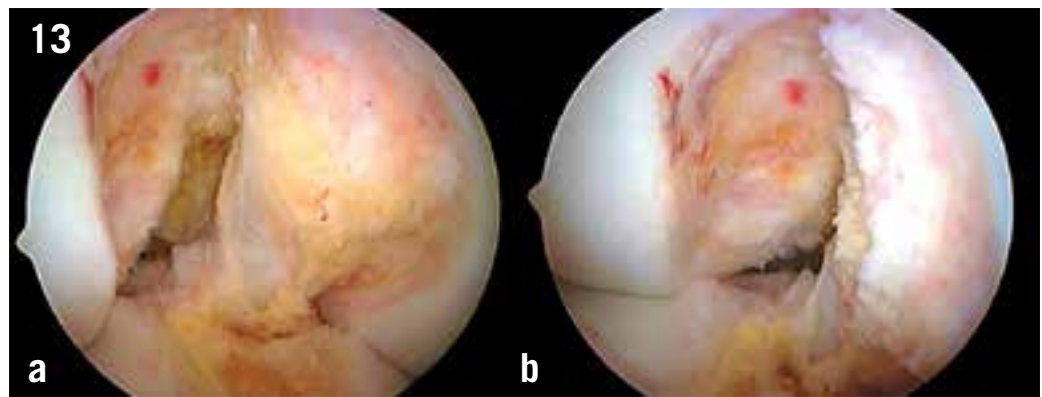Transtibial surgical technique

The transtibial surgical technique was developed in the early 1990s²⁵. In this surgical technique the ACL femoral tunnel was drilled through the ACL tibial tunnel (Figure 10). Until recently, this surgical technique was the one most commonly used by knee surgeons to perform an ACL reconstruction^{22,26}. The popularity of this surgical technique resulted from the fact that it eliminated the need for a second incision, thus decreasing operating time and surgical morbidity and improving cosmesis²⁵. Another reason for the popularity of this technique was the fact that the use of an offset femoral aimer made the procedure reproducible in the hands of the average knee surgeon.

However, in the transtibial technique, the ACL femoral tunnel position was linked to the position of the ACL tibial tunnel. To meet the simultaneous requirements of isometric femoral tunnel placement and avoidance of roof impingement of the ACL graft, it was necessary to drill a tibial tunnel located in the posterior half of the native ACL tibial attachment site^{3,4,25}. As discussed earlier, the combination of a posterior tibial tunnel position and a high, deep femoral tunnel position often produced a vertical ACL graft^{3,7-14} (Figure 11). Advocates of the transtibial technique claim that it is possible to position the ACL femoral tunnel in the centre of the ACL femoral attachment site using a transtibial technique. However, it has been demonstrated that in order to position the ACL femoral tunnel in the centre of the ACL femoral attachment site, a very medial and proximal starting position for the ACL tibial tunnel must be chosen²⁷. This starting position may result in a very short tibial tunnel which limits

the length of the ACL graft available for healing in the tibial tunnel. A short tibial tunnel may also result in a graft-tunnel mismatch which can compromise fixation of bone-patellar tendon-bone grafts. In the transtibial technique, anatomic ACL femoral tunnel placement is facilitated by drilling a 10 to 11 mm diameter tibial tunnel. A large diameter tibial tunnel may allow the offset femoral tunnel to be rotated down the lateral wall of the intercondylar notch, thus achieving a more anatomic placement of the ACL femoral tunnel. However, due to the smaller size of tibial tunnels used for hamstring tendon ACL reconstructions, the transtibial drilling technique does not allow the surgeon to position the ACL femoral tunnel for a hamstring tendon ACL reconstruction within the native ACL femoral attachment site²⁸. As a result of biomechanical and clinical studies demonstrating that improved rotational stability can be obtained with other surgical techniques which use independent drilling

Figure 13: a) Anterolateral portal view of the ACL attachment site. b) Anteromedial portal view of the ACL femoral attachment site.



of the ACL femoral tunnel, the popularity of the transtibial surgical technique has decreased^{4,7-14,22,26,29,30}.

Medial portal surgical technique

The medial portal surgical technique for ACL reconstruction was first developed to address the issues of ACL graft laceration, violation of the posterior wall of the ACL femoral tunnel, divergence of ACL femoral interference screws and tunnel-graft-length mismatch associated with bone-patellar tendon-bone autograft ACL reconstructions performed using the transtibial technique¹. In the medial portal surgical technique the ACL femoral tunnel is drilled through an anteromedial or accessory anteromedial portal with the knee flexed to 120° or higher (Figure 12). This approach provides several advantages compared to the traditional transtibial technique:

1. First of all, the ACL femoral tunnel is drilled independently of the tibial tunnel which allows the ACL femoral tunnel to be placed within the native ACL femoral attachment site, 100% of the time²³.
2. Secondly, the intra-articular position and the angle of the ACL tibial tunnel do not have to be compromised to accommodate drilling of the ACL femoral tunnel. Therefore, the surgeon can position the tibial tunnel in the centre of the footprint and is free to drill a steeper and thus longer tibial tunnel. A longer tibial tunnel minimises the potential for graft-tunnel length mismatch and allows longer bone-tendon-bone graft constructs to be utilised.

3. Thirdly, in the medial portal technique, femoral interference fixation screws are inserted through the same medial portal which was used to drill the ACL femoral tunnel, thus minimising screw-tunnel divergence.
4. Finally, the medial portal technique provides improved arthroscopic visualisation during ACL femoral tunnel drilling since the femoral tunnel can be drilled under ideal arthroscopic conditions without the loss of joint distension due to fluid extravasation out of the tibial tunnel.

As a result of these advantages, the medial portal technique has become the preferred surgical technique for performing ACL reconstruction^{11,22}.

THE KEYS TO PERFORMING ANATOMIC ACL SURGERY

Anatomic ACL surgery is facilitated by viewing the ACL femoral attachment site through the AM portal^{12,15,31}. Traditionally, the ACL femoral attachment site is viewed by placing the arthroscope in the anterolateral (AL) portal³¹. However, viewing the ACL femoral attachment site through the AL portal gives the surgeon a tangential view of the ACL femoral attachment site

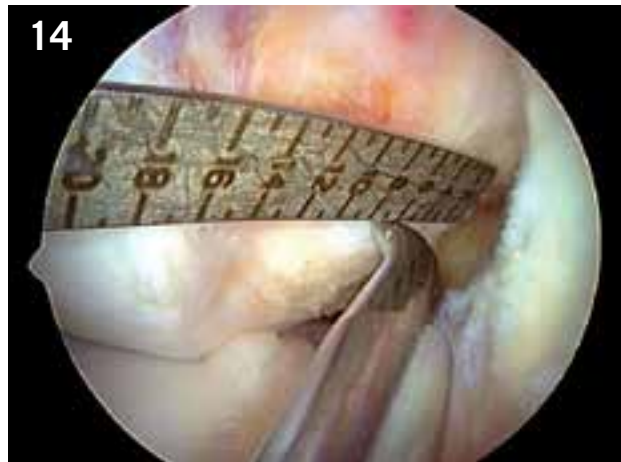


Figure 14: Anteromedial portal view of the ACL femoral attachment site. The ACL ruler is introduced through the anterolateral portal and the length of the ACL femoral footprint measured (14 mm). A 45 degree microfracture awl is introduced into the notch through the anterolateral portal and used to mark the centre of the ACL femoral footprint (7 mm).

which compromises spatial orientation in the shallow-deep direction^{1,2,15,31}. Viewing the ACL femoral attachment site through the AM portal gives the surgeon a 'face on' view of the ACL femoral attachment site which allows accurate spatial orientation in both the high-low and shallow-deep directions^{1,2,15,31} (Figure 13). As a result, the AM portal is the preferred portal for viewing the ACL femoral attachment site.

Clock-face reference method

The clock-face reference method has often been used to determine the location of the ACL femoral tunnel^{2,15}. However, the clock-face reference method has several shortcomings:

1. it ignores the depth of the intercondylar notch,
2. there is no agreed upon reference position for the 3 and 9 o'clock locations,
3. it relies on no known anatomic landmarks and
4. it cannot be used when viewing the ACL femoral attachment site through the AM portal^{1,2,15}.

Due to the above limitations, the clock-face reference has a limited role to play when performing an anatomic ACL reconstruction.

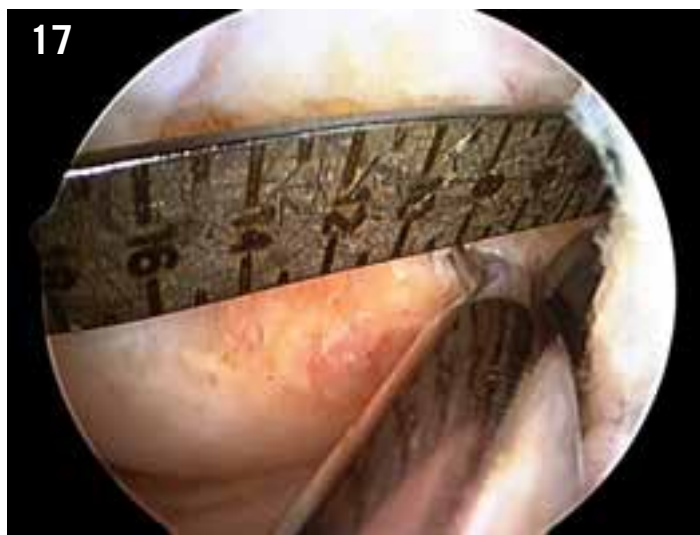
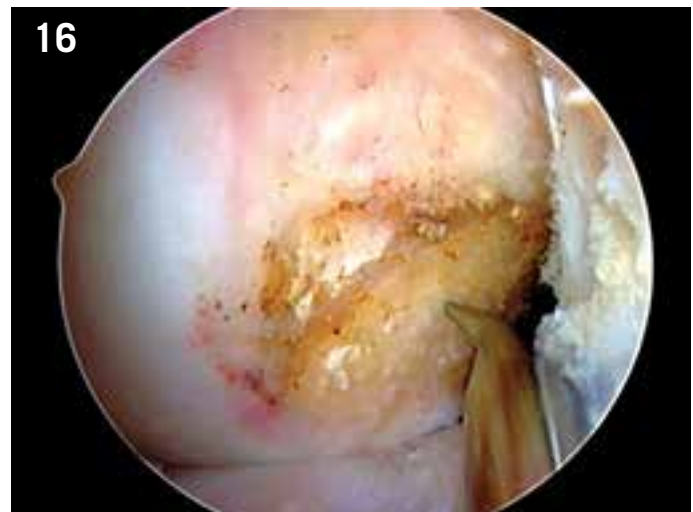
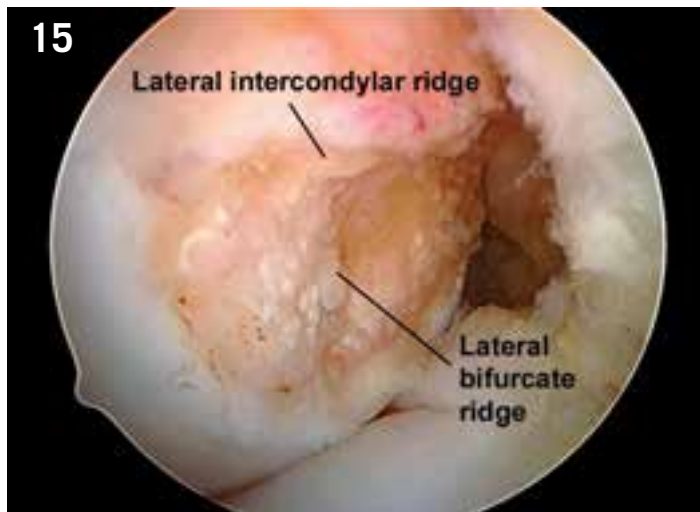


Figure 15: Anteromedial portal view. A thermal probe was used to remove soft tissue at the ACL femoral attachment site exposing the lateral intercondylar and bifurcate ridges.

Figure 16: The lateral intercondylar and bifurcate ridges are used as references to determine the centre of the ACL femoral attachment site.

Figure 17: ACL ruler method. The length of the ACL femoral attachment site is measured from the deep (proximal) articular cartilage border to the shallow (distal) articular cartilage border and marked at 45 to 50% from deep starting position.

ACL femoral tunnel position is more accurately specified and located using the following methods.

Native ACL footprint

In most situations there are remnants of the native ACL footprint present to aid with anatomic ACL femoral tunnel placement¹. The borders of the ACL femoral attachment site are marked with a 90° electrocautery or thermal probe and the centre of the ACL femoral attachment site can be estimated using the 'eyeball' method. Although the eyeball method is fairly accurate for estimating the high-low position of the ACL femoral tunnel, due to distortion of the visual field that occurs with the use of a 30° angled arthroscope, this method tends to position the ACL femoral tunnel shallow relative to the true centre of the attachment site. The true centre of the ACL femoral attachment site can be more accurately located by using an ACL ruler to directly measure the length of the ACL femoral attachment site (Figure 14).

Lateral intercondylar and bifurcate ridges

When there are no remnants of the native ACL femoral footprint present, the underlying bony morphology of the ACL femoral attachment site can be used to assist with anatomic ACL femoral tunnel placement. The ACL femoral attachment site is defined by two bony ridges, the lateral intercondylar and the lateral bifurcate ridges³²⁻³⁵ (Figure 15). The lateral intercondylar ridge is an important anatomic landmark since the native ACL always attaches inferior to the lateral intercondylar ridge³²⁻³⁵. The lateral intercondylar ridge can be identified arthroscopically in 88% of sub-acute and chronic ACL deficient knees and therefore is a consistent anatomic landmark to assist the knee surgeon with placement of the ACL femoral tunnel³⁵. The lateral bifurcate ridge, which can be identified arthroscopically in 48% of sub-acute and chronic knees, runs perpendicular to the lateral intercondylar ridge and divides the ACL femoral attachment site

into the attachment site areas for the PL and AM bundles^{32,35}. The centre of the ACL femoral attachment site is 1.7 mm deep or proximal to the bifurcate ridge and 7.3 to 8.5 mm superior or anterior to the inferior or posterior articular cartilage margin of the lateral femoral condyle³⁶ (Figure 16).

ACL ruler

Use of a malleable ACL ruler allows the knee surgeon to individualise the location of the ACL femoral tunnel based on the specific anatomy of the patient^{1,2,15,37}. This approach allows for 'a la carte' or patient-specific surgery to be performed, vs the 'one size fits all' approach associated with the use of offset ACL femoral aimers. This technique is particularly useful for revision ACL reconstructive surgery where there are no ACL remnants present and the bony landmarks may have been destroyed by prior notchplasty or the previous ACL femoral bone tunnel. The ruler is positioned along the lower-third of the lateral wall

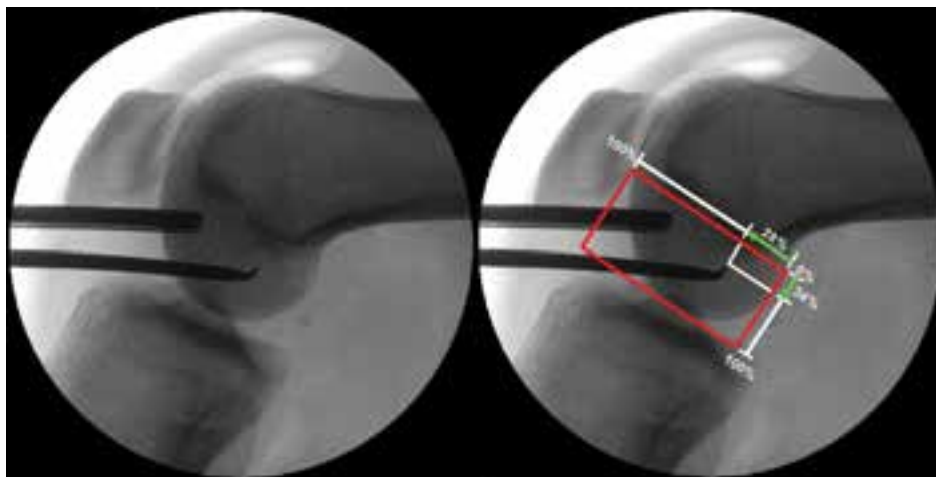


Figure 18: Intraoperative c-arm image. a) True lateral image of the knee with the tip of the 45° microfracture awl at the proposed ACL femoral tunnel location. b) The Bernard and Hertel grid is used to specify the femoral tunnel location.

of the intercondylar notch. The centre of the ACL femoral tunnel is located at a shallow-deep position that is 45 to 50% of the measured distance from the deep (proximal) articular cartilage border to the shallow articular cartilage border (Figure 17). This point has been validated by Bird et al³⁷ as a good approximation to the centre of the ACL femoral attachment site.

Intraoperative fluoroscopy

At the present time, interoperative fluoroscopy is the most accurate and reproducible method for ACL femoral tunnel placement³⁸⁻³⁹. Fluoroscopy gives the surgeon the ability to precisely measure and if needed change the ACL femoral tunnel position during the surgical procedure. Fluoroscopy is especially valuable in revision cases where there will usually be no remnants of the native ACL present and the bony anatomy of the ACL

femoral attachment site has been altered or removed by prior notchplasty and the previous ACL femoral tunnel. Fluoroscopy is also extremely helpful when attempting to preserve remnants of the torn ACL or performing an augmentation technique for a partial ACL tear. In these situations, identification of the lateral intercondylar and bifurcate ridges is not feasible as this would require resection of intact ACL fibres to expose the lateral wall of the notch. The ruler technique is also not possible in this situation since the intact ACL fibres prevent accurate positioning of the ruler along the lateral wall of the notch. Using fluoroscopy, the proper placement of the ACL femoral tunnel can be easily accomplished without the need to rely on remnants of the native ACL, measurements along the lateral wall of the notch or the bony anatomy of the ACL femoral attachment site. The grid system described by Bernard and Hertel⁴⁰ is used

to locate the centre of the ACL femoral attachment site (Figure 18). This method is easy to use, is reproducible and has been shown to be independent of the knee size, shape and the distance between the X-ray tube and the patient.

Using any or all of the above guidelines eliminates the need to use an offset ACL femoral aimer and referencing off the 'over-the-top' position to determine ACL femoral tunnel placement. ACL femoral offset aimers can constrain the location of the femoral guide pin and can lead to non-anatomic placement of the ACL femoral tunnel. The above guidelines allow the surgeon to select and verify the location of the ACL femoral tunnel position using established anatomic and radiographic landmarks.

SUMMARY

Over the last decade the concept of ACL reconstruction has evolved from a surgical technique which focused on the concepts of isometry and avoidance of graft impingement to a surgical technique based on reproducing the anatomy of the native ACL as closely as possible. The stimulus for this change was the recognition that non-anatomic ACL reconstructions often failed to control rotational stability of the knee. The goal of SB ACL reconstruction is to place the ACL replacement at the centre of the native ACL attachment sites. This goal is best accomplished by using an outside-in or medial portal surgical technique and using recognised anatomic landmarks such as the native ACL footprint and the ACL ridges or by using an ACL ruler or fluoroscopy to obtain anatomic placement of the ACL femoral tunnel.

“ **interoperative fluoroscopy is the most accurate and reproducible method for ACL femoral tunnel placement** ”

References

1. Brown CH, Spalding T, Robb C. Medial portal technique for single-bundle anatomical anterior cruciate (ACL) reconstruction. *Int Orthop* 2013; 37:253-269.
2. Karlsson J, Irrgang JJ, van Eck CF, Samuelsson K, Mejia HA, Fu FH. Anatomic single- and double-bundle anterior cruciate ligament reconstruction, part 2: clinical application of surgical technique. *Am J Sport Med* 2011; 39:2016-2026.
3. Marchant B, Noyes F, Barber-Westin S, Fleckenstein C. Prevalence of nonanatomical graft placement in a series of failed anterior cruciate ligament reconstruction. *Am J Sports Med* 2010; 38:1987-1996.
4. Kopf S, Forsythe B, Wong AK, Tashman S, Anderst W, Irrgang JJ et al. Nonanatomic tunnel position in traditional transtibial single-bundle anterior cruciate ligament reconstruction evaluated by three-dimensional computed tomography. *J Bone Joint Surg Am* 2010; 92:1427-1431.
5. Bach BR. Arthroscopy-assisted patellar tendon substitution for anterior cruciate ligament insufficiency. *Surgical technique. Am J Knee Surg* 1989; 2:3-20.
6. Bach BR, Tradonsky S, Bojchuk J, Levy ME, Bush-Joseph CA, Khan NH. Arthroscopically assisted anterior cruciate ligament reconstruction using patellar tendon autograft. Five- to nine-year follow-up evaluation. *Am J Sports Med* 1998; 26:20-29.
7. Driscoll MD, Isabell GP, Conditt MA, Ismaily BS, Jupiter DC, Noble PC. Comparison of 2 femoral tunnel locations in anatomic single-bundle anterior cruciate ligament reconstruction: a biomechanical study. *Arthroscopy* 2012; 28:1481-1489.
8. Kato Y, Ingham SJ, Kramer S, Smolinski P, Saito A, Fu FH. Effect of tunnel position for anatomic single-bundle ACL reconstruction on knee biomechanics in a porcine model. *Knee Surg Sports Traumatol Arthrosc* 2010; 18:2-10.
9. Kato Y, Maeyama A, Lertwanich P, Wang JH, Ingham SJ, Kramer S et al. Biomechanical comparison of different graft positions for single-bundle anterior cruciate ligament reconstruction. *Knee Surg Sports Traumatol Arthrosc* 2013; 21:816-823.
10. Kondo E, Merican AM, Yasuda K, Amis AA. Biomechanical comparison of anatomic double-bundle, anatomic single-bundle, and nonanatomic single-bundle anterior cruciate ligament reconstruction. *Am J Sports Med* 2011; 39:279-288.
11. Loh JC, Fukuda Y, Tsuda E, Steadman RJ, Fu FH, Woo SL. Knee stability and graft function following anterior cruciate ligament reconstruction: comparison between the 11 o'clock and 10 o'clock femoral tunnel placement. 2002 Richard O'Connor Award paper. *Arthroscopy* 2003; 19:297-304.
12. Musahl V, Plakseychuk A, VanScyoc AH, Sasaki T, Debski RE, McMahon PJ et al. Varying femoral tunnels between the anatomical footprint and isometric positions: effect on kinematics of the anterior cruciate ligament-reconstructed knee. *Am J Sports Med* 2005; 33:712-718.
13. Scopp JM, Jasper LE, Belkoff SM, Moorman CT. The effect of oblique femoral tunnel placement on rotational constraint of the knee reconstructed using patellar tendon autografts. *Arthroscopy* 2004; 20:294-299.
14. Yamamoto Y, Hsu WH, Woo SL, Van Scyoc A, Takakura Y, Debski RE. Knee stability and graft function after anterior cruciate ligament reconstruction: a comparison of a lateral and an anatomical femoral tunnel placement. *Am J Sports Med* 2004; 32:1825-1832.
15. van Eck CF, Lesmiak BP, Schreiber VM, Fu FH. Anatomic single- and double-bundle anterior cruciate ligament reconstruction flowchart. *Arthroscopy* 2010; 26:258-268.
16. Hussein M, van Eck CF, Cretnik A, Dinevski D, Fu FH. Prospective randomized clinical evaluation of conventional single-bundle, anatomic single-bundle, and anatomic double-bundle anterior cruciate ligament reconstruction: 281 cases with 3- to 5-year follow-up. *Am J Sports Med* 2012; 40:512-520.
17. Hussein M, van Eck CF, Cretnik A, Dinevski D, Fu FH. Individualized anterior cruciate ligament surgery: a prospective study comparing anatomic single- and double-bundle reconstruction. *Am J Sports Med* 2012; 40:1781-1788.
18. Hofbauer M, Muller B, Murawski CD, van Eck CF, Fu FH. The concept of individualized anatomic anterior cruciate ligament (ACL) reconstruction. *Knee Surg Sports Traumatol Arthrosc* 2013; epub ahead of print.
19. Siebold R. The concept of complete footprint restoration with guidelines for single- and double-bundle ACL reconstruction. *Knee Surg Sports Traumatol Arthrosc* 2011; 19:699-706.
20. Magnussen RA, Lawrence JT, West RL, Toth AP, Taylor DC, Garrett WE. Graft size and patient age are predictors of early revision after anterior cruciate ligament reconstruction with hamstring autograft. *Arthroscopy* 2012; 28:526-531.
21. Park SY, Oh H, Park S, Lee JH, Lee SH, Yoon KH. Factors predicting hamstring tendon graft diameters and resulting failure rates after anterior cruciate ligament reconstruction. *Knee Surg Sports Traumatol Arthrosc* 2013; 21:1111-1118.
22. Chechik O, Amar E, Khashan M, Lador R, Eyal G, Gold A. An international survey on anterior cruciate ligament reconstruction practices. *Int Orthop* 2013; 37:201-206.
23. Kaseta MK, DeFrate LE, Charnock BL, Sullivan RT, Garrett WE. Reconstruction technique affect femoral tunnel placement in ACL reconstruction. *Clin Orthop Relat Res* 2008; 466:1467-1474.
24. Steiner ME, Battaglia TC, Heming JF, Rand JD, Festa A, Baria M. Independent drilling outperforms conventional transtibial drilling in anterior cruciate ligament reconstruction. *Am J Sports Med* 2009; 37:1912-1919.
25. Hardin GT, Bach BR, Bush-Joseph CA. Endoscopic single-incision anterior cruciate ligament reconstruction using patellar tendon autograft. *Am J Knee Surg* 1992; 5:144-155.
26. Duquin TR, Wind WM, Fineberg MS, Smolinski RJ, Buyea CM. Current trends in anterior cruciate ligament reconstruction. *J Knee Surg* 2009; 22:7-12.



27. Piasecki DP, Bach BR, Espinoza Orias AA, Verma NN. Anterior cruciate ligament reconstruction: can anatomic femoral placement be achieved with a transtibial technique? *Am J Sports Med* 2011; 39:1306-1315.
28. Strauss EJ, Barker JU, McGill K, Cole BJ, Bach BR, Verma NN. Can anatomic femoral tunnel placement be achieved using a transtibial technique for hamstring anterior cruciate ligament reconstruction? *Am J Sports Med* 2011; 39:1263-1269.
29. Bedi A, Musahl V, Steuber V, Kendoff D, Choi D, Allen AA et al. Transtibial versus anteromedial portal reaming in anterior cruciate ligament reconstruction: an anatomic and biomechanical evaluation of surgical technique. *Arthroscopy* 2011; 27: 380-390.
30. Chalmers PN, Mall NA, Cole BJ, Verma NN, Bush-Joseph CA, Bach BR. Anteromedial versus transtibial tunnel drilling in anterior cruciate ligament reconstructions: a systematic review. *Arthroscopy* 2013; 29:1235-1242.
31. Araujo PH, van Eck CF, Macalena JA, Fu FH. Advances in the three-portal technique for single- or double-bundle ACL reconstruction. *Knee Surg Sports Traumatol Arthrosc* 2011; 19:1239-1242.
32. Ferretti M, Ekdahl M, Shen W, Fu F. Osseous landmarks of the femoral attachment of the anterior cruciate ligament: an anatomic study. *Arthroscopy* 2007; 23: 1218-1225.
33. Purnell ML, Larson AI, Clancy W. Anterior cruciate ligament insertions on the tibia and femur and their relationships to critical bony landmarks using high-resolution volume-rendering computed tomography. *Am J Sports Med* 2008; 36:2083-2090.
34. Shino K, Suzuki T, Iwahashi T, Mae T, Nakamura N, Nakata K et al. The resident's ridge as an arthroscopic landmark for anatomical femoral tunnel drilling in ACL reconstruction. *Knee Surg Sports Traumatol Arthrosc* 2010; 18:1164-1168.
35. van Eck CF, Morse KR, Lesniak BP, Kropf EJ, Tranovich MJ, van Dijk et al. Does the lateral intercondylar ridge disappear in ACL deficient patients? *Knee Surg Sports Traumatol Arthrosc* 2010; 18:1184-1188.
36. Ziegler CG, Pietrini SD, Westerhaus BD, Anderson CJ, Wijdicks CA, Johansen S et al. Arthroscopically pertinent landmarks for tunnel positioning in single-bundle and double-bundle anterior cruciate ligament reconstructions. *Am J Sports Med* 2011; 39:743-752.
37. Bird J, Carmont M, Dhillon M, Smith N, Brown C, Thompson P et al. Validation of a new technique to determine midbundle femoral tunnel position in anterior cruciate ligament reconstruction using 3-dimensional computed tomography analysis. *Arthroscopy* 2011; 27:1259-1267.
38. Passler H, Höher J. [Intraoperative quality control of the placement of bone tunnels for the anterior cruciate ligament.] *Unfallchirurg* 2004; 107: 263-272.
39. Lobenhoffer P, Bernard M, Agneskirchner J. [Quality assurance in cruciate ligament surgery.] *Arthroscopie* 2003; 16: 202-208.
40. Bernard M, Hertel P, Hornung H, Cierpinski T. Femoral insertion of the ACL. Radiographic quadrant method. *Am J Knee Surg* 1997; 10:14-22.

Charles H. Brown Jr, M.D.
 Medical Director and Consultant
 Orthopaedic Surgeon
 International Knee & Joint Centre
 Abu Dhabi, United Arab Emirates
 Contact:
 charliebrowngoestosa@yahoo.com