

Morphology of Anterior Cruciate Ligament Attachments for Anatomic Reconstruction: A Cadaveric Dissection and Radiographic Study

Philippe Colombet, M.D., James Robinson, M.S., F.R.C.S.(Orth.), Pascal Christel, M.D., Jean-Pierre Franceschi, M.D., Patrick Djian, M.D., Guy Bellier, M.D., and Abdou Sbihi, M.D.

Purpose: To define the positions of the attachments of the anteromedial (AM) and posterolateral (PL) bundles of the anterior cruciate ligament (ACL). **Methods:** The shape and positions of the femoral and tibial attachments of the 2 bundles relative to bony landmarks were measured in 7 fresh-frozen, unpaired cadaveric knees by 6 independent observers. Metallic marker beads were then inserted into the defined anatomic points, and plain radiographs of the specimens were taken. We used the line described by Amis and Jakob on the tibia and the grid prepared by Bernard et al. for the femur to define AM and PL bundle attachment positions. **Results:** In the cadaveric specimens, referencing the position of the AM bundle tibial attachment from the retro-eminence ridge (RER) resulted in the least interobserver error. On tibial radiographs, the distance between the posterior tibial cortex and the perpendicular projection of the center of the AM bundle attachment onto Amis and Jakob's line was 35.6 ± 5.1 mm. The ratio of this distance to the length of Amis and Jakob's line (from the anterior cortex) was $36\% \pm 3.8\%$ (and $52\% \pm 3.4\%$ for the center of the PL bundle). On the femur, the center of the AM bundle was situated at $26.4\% \pm 2.6\%$, and the center of the PL bundle at $32.3\% \pm 3.9\%$, along the length of Blumensaat's line. **Conclusions:** The RER provides an easily identifiable and accurate reference point that can be used clinically. On a lateral radiograph, the positions of the tibial attachments can be referenced to Amis and Jakob's line. This method, different from Blumensaat's line, is independent of knee flexion. **Clinical Relevance:** This study details anatomically and radiologically the positions of the attachments of the AM and PL bundles of the ACL. This could assist with accurate tunnel placement in reconstruction surgery and provide reference data for postoperative radiographic evaluation. **Key Words:** Double-bundle ACL reconstruction—Anatomic ACL reconstruction—ACL morphology—Reference landmarks—ACL attachments.

From the Centre de Chirurgie Orthopédique et Sportive (P.C., J.R.), Bordeaux-Mérignac; Institut de l'Appareil Locomoteur Nolle, Paris et Hôpital privé Paul d'Égine (P.C., P.D.), Champigny-sur-Marne; Service du Professeur Curvale, Hôpital de la Conception (J-P.F., A.S.), Marseille; and Cabinet Goethe (P.D., G.B.), Paris, France.

The authors have consulting relationships with Smith & Nephew Endoscopy, Andover, Massachusetts. J.R. held the post of Fellow at the Centre de Chirurgie Orthopédique et Sportive, funded by Smith & Nephew Endoscopy. Research performed at the Department d'Anatomie, Université de Tours.

Address correspondence and reprint requests to Philippe Colombet, M.D., Centre de Chirurgie Orthopédique et Sportive, 9 rue Jean Moulin, 33700 Bordeaux-Mérignac, France. E-mail: contact@planete-ortho.com

© 2006 by the Arthroscopy Association of North America
0749-8063/06/2209-5195\$32.00/0
doi:10.1016/j.arthro.2006.04.102

Anterior cruciate ligament (ACL) reconstruction techniques have improved steadily over the past 20 years. During the 1990s, surgeons concentrated on developing simpler and less invasive techniques, but recently, interest has turned to trying to reconstruct the ACL in a way that better replicates its anatomy and function. Palmer,¹ in 1938, was one of the first authors to describe the ACL as consisting of anteromedial (AM) and posterolateral (PL) fiber bundles. This description was refined by Brantigan and Voshell² and Girgis et al.,³ and, although Odensten and Gillquist⁴ found no histologic evidence to separate the ligament into distinct components, it is now generally recognized that the native ACL does not behave as a simple band of fibers with constant tension. The separation of this ligament into AM and PL fiber bundles has now

been widely accepted as a basis of understanding of the function of the ACL⁵⁻¹² (although Amis and Dawkins in 1991 divided the ACL into anteromedial, intermediate, and posterolateral bundles¹²).

The description of AM and PL is based on the relative anatomic positions of the bundle attachments on the tibia.¹³ At the femoral attachment, the AM bundle lies more anterior and proximal (“higher” and “deeper” in the notch according to the surgical navigation terminology described by Amis and Jakob¹³) to the PL bundle, which is relatively more posterior and inferior (“lower” and “shallower”) on the lateral wall of the intercondylar notch. Biomechanically, the 2 bundles have different tensioning patterns throughout the full range of knee flexion. The AM bundle better restrains anterior tibia translation at greater than 45° of knee flexion,^{14,15} whereas the PL bundle has been shown to be less isometric and a more important restraint toward full extension.¹⁶

In performing an “anatomic” ACL reconstruction, with both AM and PL bundle grafts, knowledge of the anatomy of these fiber bundles is critical. It has been shown that despite rigorous training, arthroscopic surgeons may have difficulty in accurately placing the drill holes for single-bundle reconstruction,¹³ and so, for 2-bundle reconstruction, the ability to reference reproducibly the relative positions of the bundles from consistent landmarks, particularly on the tibial side, is essential. Although some studies have described various landmarks from which tunnel positions may be referenced during standard single-bundle ACL reconstruction,¹⁷⁻¹⁹ quantitative data specific to anatomic reconstruction are lacking. Similarly, although reference data are available in the literature for use by surgeons in checking single-bundle tunnel positioning radiographically,^{20,21} no data relate to the placement of separate AM and PL bundle grafts.

The objective of this study was therefore to define the position and morphology of the tibial and femoral attachment areas of AM and PL bundles in cadaveric knees. With the use of bony landmarks and standard radiologic referencing methods, we tested the hypothesis that reliable positions for the AM and PL bundle attachments could be established. This information could be used to assist tunnel placement during arthroscopic “anatomic” ACL reconstruction and to radiologically confirm correct bundle placement.

METHODS

This study was performed on 7 fresh-frozen cadaveric knees (5 left and 2 right; mean age, 75 years;

standard deviation [SD], 6.3) that were obtained under a protocol approved by the local research ethics committee. No joints were paired, so measurements were as diverse as possible. Knees with surgical scars, ACL rupture, or significant osteoarthritis (grade 3 or greater) were excluded. Specimens were prepared by removal of all soft tissues, with the exception of the ACL. Knees were then flexed and extended to allow identification of the AM and PL bundles. Two groups of fiber bundles could be clearly identified in each knee: AM bundle fibers became taut in flexion, whereas PL bundle fibers were identified by the fact that they were taut in extension. Bundles were then gently separated through blunt dissection, and a suture of a different color was passed around each one. This allowed the bundles to be further separated and followed to their tibial and femoral attachments. With an oscillating saw, the femur was then divided in the sagittal plane, from the roof of the intercondylar notch. This allowed better visualization of the femoral attachment area. A fine marker pen was then used to trace around the periphery of the AM and PL bundles at the femoral and tibial attachments. After this was done, both bundles were divided transversely in their midsubstance. On the tibia of each specimen, we also located the curved eminence that lay just anterior to the anterior extent of the tibial attachment of the PCL—previously described by McGuire et al.²² as the “over-the-back” ridge. This we named the retro-eminence ridge (RER) to avoid confusion with the over-the-top position on the femur.

Six different examiners (all orthopaedic surgeons with a specialty interest in arthroscopic knee surgery) were then provided with Figs 1 and 2 and used Vernier calipers to independently measure the following distances in each specimen:

1. On the tibial plateau (Fig 1):

- Anteroposterior diameter of the ACL attachment area (**ab**)
- Mediolateral diameter of the ACL attachment area (**cd**)
- Anteroposterior diameter of the tibial plateau (**hi**)
- Mediolateral diameter of the tibial plateau (**ml**)
- Distance between the center of the AM bundle and the RER (**eg**)
- Distance between the center of the AM bundle and the center of the PL bundle (**ef**)
- Distance between the center of the AM bun-

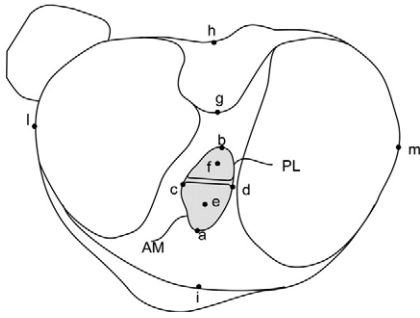


FIGURE 1. Tibia in the axial view with tibial measurement points (**a-m**). Both anatomic and corresponding surgical navigation terminology⁹ have been used for clarity. (**a**, anterior extent of the ACL attachment area; **b**, posterior extent of the ACL attachment area; **c**, medial extent of the ACL attachment area; **d**, lateral extent of the ACL attachment area; **e**, projection of the center of the AM bundle onto the ACL attachment area; **f**, projection of the center of the PL bundle onto the ACL attachment area; **g**, retro-eminence ridge (RER); **h**, posterior border of the tibial plateau; **i**, anterior border of the tibial plateau; **l**, lateral border of the tibial plateau; **m**, medial border of the tibial plateau).

dle and the posterior border of the ACL attachment area (**be**)

- Distance between the center of the PL bundle and the anterior border of the ACL attachment area (**af**)
 - Distance between the posterior border of the ACL attachment area and the RER (**bg**)
 - Distance between the anterior border of the ACL attachment area and the anterior border of the tibial plateau (**ai**)
 - Distance between the posterior border of the ACL attachment area and the posterior border of the tibial plateau (**bh**)
2. On the femur (Fig 2):
- Proximodistal diameter of the ACL attachment area (**AB**)
 - Anteroposterior diameter of the ACL attachment area (**CD**)
 - Distance between the proximal border of the ACL attachment and the center of the AM bundle (**BE**)
 - Distance between the distal border of the ACL attachment and the center of the PL bundle (**AF**)
 - Distance between the center of the AM bundle and the center of the PL bundle (**EF**)
 - Distance between the proximal border of the ACL attachment and the over-the-top position (**BI**)
 - Distance between the distal border of the

ACL attachment and the adjacent margin of the articular cartilage (**AH**)

- Distance between the posterior extent of the ACL attachment and the adjacent articular surface (**DG**)
- Distance between the most anterior point of the roof of the notch and the over-the-top position (**IJ**)

The center of each attachment was defined as the “parallel projection” of the central fibers of the bundle onto its attachment. Every examiner measured each specimen once. The mean of these 6 values was taken, and interobserver variability was calculated. Measurements **ai**, **bh**, and **bg** were taken specifically to allow comparison with previous studies.^{3,19,21}

Metallic beads (2 mm) were then inserted into the bone to mark mean positions of points **A** to **H** on the femur and **a** to **I** on the tibia. A 2-mm-diameter wire was used to mark the outline of the RER. To render the tibiae and femora “dry bone” specimens, the soft tissue was removed and they were then boiled in water for 48 hours. Hydrogen-peroxide was added during the last 30 minutes of boiling, and

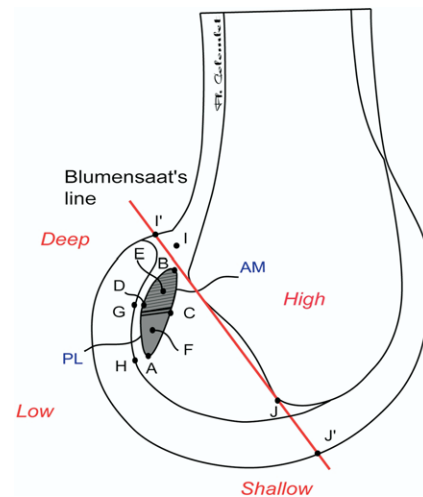


FIGURE 2. Femur in the sagittal view with femoral measurement points (**A-J**). Both anatomic and corresponding surgical navigation terminology⁸ have been used for clarity. **A**, distal border of the ACL attachment area (“low” in the notch); **B**, proximal border of the ACL attachment area (“high” in the notch); **C**, anterior border of the ACL attachment area (“shallow” in the notch); **D**, posterior border of the ACL attachment area (“deep” in the notch); **E**, projection of the center of the AM bundle onto the ACL attachment area; **F**, projection of the center of the PL bundle onto the ACL attachment area; **G**, posterior margin of the articular cartilage (“deep” in the notch); **H**, distal margin of the articular cartilage (“low” in the notch); **I**, “over-the-top” position (“high” in the notch); **J**, most anterior point of the roof of the notch.

specimens were then dried for 24 hours. Lateral and axial plain radiographs of the tibiae and lateral plain radiographs of the femora were then taken and enlarged by 87%, so that direct measurements could be taken from them. To verify measurement accuracy, a 10-mm-diameter metal ball was placed adjacent to each specimen. From the axial radiographs, we repeated the measurements made on the anatomic specimens, as described earlier. On the lateral tibial radiographs, we marked the position of the line described by Amis and Jakob,¹³ parallel to the tibial plateau and passing through the posterior corner of the tibial epiphysis. Points **e** and **f** (the centers of the AM and PL bundles) were then orthogonally projected onto this line, allowing the positions of the tibial attachments of both bundles to be described in terms of a percentage length of Amis and Jakob's line (0% [intersection with the anterior cortex] to 100% [intersection with the posterior cortex]).

To determine the localization of points **E** and **F** (the centers of the AM and PL bundle femoral attachments) on the lateral roentgenogram, we used the quadrant method described by Bernard et al.²⁰ A grid was applied along Blumensaat's line, allowing the position of the centers of the AM and PL attachments to be defined as a percentage ratio of the sagittal diameter of the lateral condyle measured along Blumensaat's line (**I' J'**).

Statistical analysis of the data was performed with StatView software (SAS Institute, Cary, NC). A 2-tailed Student *t* test for paired data was used to compare radiologic measurements with corresponding measurements taken directly from the anatomic specimens. Significance was defined as $P < .05$, for a 95% alpha level.

RESULTS

Cadaveric Measurements

Tibial Measurements: Mean measurements for each specimen are shown in Table 1. Average dimensions of the tibial plateau were as follows: mediolateral diameter (**ml**) = 77.7 ± 5.9 mm and anteroposterior diameter (**hi**) = 50.5 ± 6.2 mm. Mean mediolateral diameter of the ACL tibial attachment was 12.7 ± 2.7 mm, and anteroposterior diameter was 17.5 ± 2.1 mm. Mean distance between the center of the AM bundle and the RER (**eg**) was 17.5 ± 1.7 mm. In comparison with the size of the individual tibia, this distance was $22.6\% \pm 2.8\%$ of the mediolateral diameter of the tibial plateau (**ml**). Average distance between the center of the AM bundle and the center of the PL bundle (**ef**) was 8.4 ± 0.6 mm. Measurements referencing the posterior border of the tibial attachment from the RER (**bg**) had less intraobserver error (SD = 1.2 mm) than did measurements (**bh**) that referenced the posterior border of the tibia (SD = 2.3 mm; $P = .005$).

An outline of the tibial ACL attachments of each specimen is shown in Fig 3. Each occupied nearly all the width of the space between the tibial spines, with individual attachment areas of the AM and PL bundles lying mediolaterally beside each other. The centers of the 2 fiber bundles, however, lay relatively more anteroposterior. The morphology of the tibial attachments was more variable than that of the femoral attachments (Fig 4) between specimens.

Femoral Measurements: Mean measurements for each specimen are shown in Table 2. Mean proximodistal diameter of the femoral attachment of the ACL was 13.9 ± 9.5 mm, and anteroposterior diameter was 9.3 ± 7.1 mm. The ACL attachment area was closely bordered by articular cartilage: **BI**, 1.8 ± 1.3 mm; **DG**, 2.5 ± 1.1

TABLE 1. Tibial Measurements Taken Directly From Cadaveric Specimens, mm

	ab	cd	be	af	ef	bg	eg	ai	bh	hi	ml
Specimen 1	20.2	11.5	7.7	6.5	8.0	7.3	15.0	13.0	24.2	52.2	80.7
Specimen 2	15.5	12.5	7.5	7.7	8.0	10.7	18.2	11.7	23.0	43.3	69.2
Specimen 3	17.2	9.3	5.2	7.0	9.2	11.0	16.2	13.8	28.0	54.2	78.5
Specimen 4	15.8	11.8	6.8	6.8	8.3	13.7	20.5	12.3	28.0	54.2	79.3
Specimen 5	18.7	15.5	8.8	9.0	9.0	10.2	19.0	14.7	26.5	55.5	84.3
Specimen 6	20.2	17.3	7.8	8.7	8.7	9.2	17.0	15.5	23.7	54.5	82.2
Specimen 7	15.5	11.0	6.2	6.2	7.7	10.3	16.5	11.0	20.8	40.0	70.0
Mean	17.6	12.7	7.1	7.4	8.4	10.3	17.5	13.1	24.9	50.5	77.7
Standard deviation	2.1	2.8	1.2	1.1	0.6	1.9	1.9	1.6	2.7	6.2	5.9
Intraobserver error	1.7	1.1	0.9	1.3	1.1	1.2	0.9	2.1	2.3	3.0	1.3

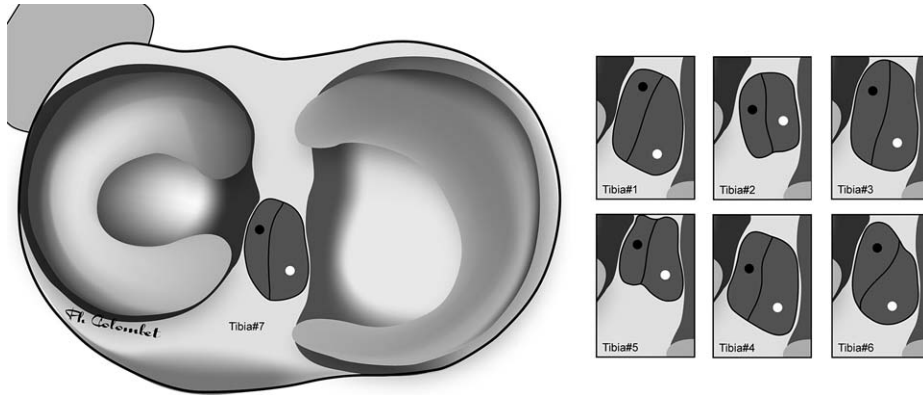


FIGURE 3. Appearances of the tibial ACL attachments (tracings transposed to appear to be on the right side). The projection of the central fibers of the AM bundle onto the attachment area is shown by a white dot (point e), and similarly, the projection of the central fibers of the PL bundle by a black dot (point f).

mm; and **AH**, 2.8 ± 1.5 mm. The morphologic appearance of the femoral attachment was more consistent than that of the tibial attachment. The AM bundle attachment lay proximally and slightly anterior (“deeper” and “higher” in the notch) to the PL bundle attachment, extending right up to the over-the-top position on the lateral condyle (Fig 4). The PL bundle attachment lay adjacent, skirting the articular surface. The projection of the center of each fiber bundle was located centrally in its corresponding attachment area. Mean distance between points **E** and **F** was 8.2 ± 1.2 mm.

Radiographic Measurements

No significant differences were observed between radiologic and cadaveric measurements, except with measurements **ai** ($P = .004$) and **hi** ($P = .006$) on the tibia and **IJ** ($P = .012$) on the femur. These, along with **bh**, were the cadaveric measurements with the highest interobserver variability ($SD > 2$ mm). Mean mediolateral diameter of the tibial epiphysis measured 75.5 ± 6 mm, and anteroposterior diameter measured

55.4 ± 6.1 mm. The average length of Amis and Jakob’s line was 55.4 ± 6.9 mm. The orthogonal projection of the center of the AM bundle (point e) lay at 36% ($SD \pm 3.8\%$) along this line, and point f (the center of the PL bundle) was located at $52\% \pm 3.4\%$, upon anterior-to-posterior measurement (Fig 5).

The position of the centers of the AM and PL bundles on the lateral femoral roentgenogram, determined with the grid system of Bernard et al.,²⁰ is shown in Fig 6. The center of the AM bundle **E** was situated on average $26.4\% \pm 2.6\%$ along the length of Blumensaat’s line, with measurement taken from point **I’**. The center of the PL bundle lay at the $32.3\% \pm 3.9\%$ position. In the axis parallel to Blumensaat’s line, the center of the AM bundle lay at $25.3\% \pm 4.2\%$, and the center of the PL bundle at $47.6\% \pm 6.5\%$.

DISCUSSION

In performing anatomic ACL reconstruction, knowledge about the ACL attachment areas and their

FIGURE 4. Femoral ACL attachments (tracings transposed to appear to be on the right side). The morphology of the femoral attachments was more uniform than that of the tibial attachments. The projection of the central fibers of the AM bundle onto the attachment area is shown by a red dot (point E), and similarly, the projection of the central fibers of the PL bundle by a green dot (point F).

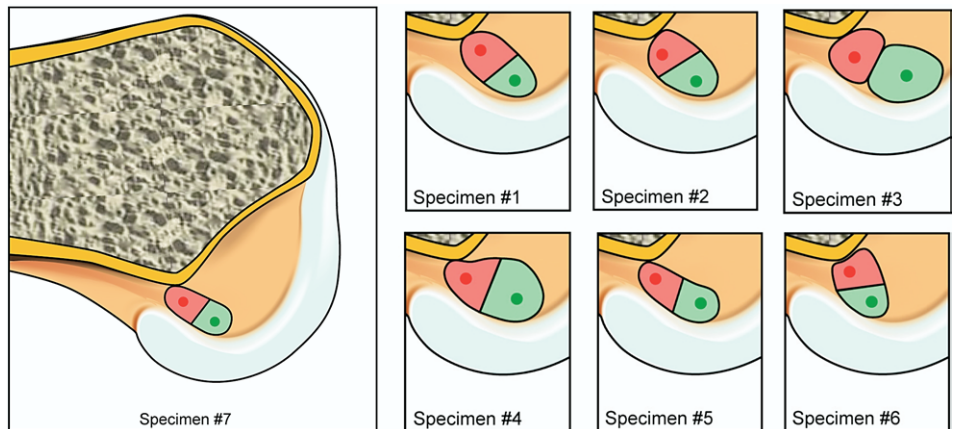


TABLE 2. Femoral Measurements Taken Directly From Cadaveric Specimens, mm

	AB	CD	BE	AF	EF	BI	AH	DG	IJ
Specimen 1	17.3	9.2	5.0	4.2	8.2	2.8	2.5	3.7	28.5
Specimen 2	14.2	7.2	4.5	3.5	5.7	3.2	2.2	2.7	23.0
Specimen 3	18.7	9.3	4.0	4.8	8.7	1.2	2.3	2.8	28.7
Specimen 4	20.2	12.8	5.3	6.7	9.5	0.2	3.0	2.5	31.2
Specimen 5	21.3	11.5	6.2	4.8	8.8	1.7	1.7	0.8	29.7
Specimen 6	18.8	14.5	7.8	5.2	8.5	3.0	6.2	3.7	27.3
Specimen 7	17.7	7.8	4.2	4.7	8.0	0.3	2.0	1.3	22.2
Mean	18.3	10.3	5.3	4.8	8.2	1.8	2.8	2.5	27.2
Standard deviation	2.3	2.7	1.3	1.0	1.2	1.3	1.5	1.1	3.4
Intraobserver error	1.1	1.1	0.4	0.7	0.8	0.9	0.9	0.7	2.5

positions relative to reproducible landmarks is essential for accurate tunnel placement. The anatomic form of the native tibial attachment is a matter of particular concern for ACL reconstruction. The native tibial “footprint” allows the ACL fibers to tuck under the roof of the intercondylar notch, and the anterior part of the distal third of the ligament has been shown to lie in direct contact with the intercondylar fossa in full knee extension—so-called “physiologic impingement.”²³ Cellular morphology in this part of the ligament is also different when compared with typical ligament structure. The region is relatively more avascular, with histologic sections showing typical tenocytes and chondrocyte-like cells.²³ Their presence could be explained as a functional adaptation of the ligament to recurring compressive stress caused by direct contact of bone and ligament. Common grafts cannot replicate the appearance of the native “footprint” (although some expansion of the distal end of the graft and redevelopment, to some extent, of the

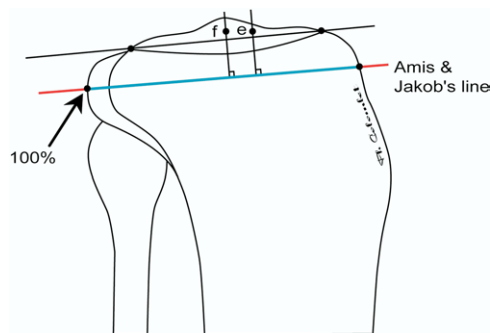


FIGURE 5. Tibia in the sagittal plane with Amis and Jakob’s line passing through the posterior corner of the tibial plateau and parallel to the medial tibial joint surface. The center of the AM bundle attachment *e* and the center of the PL bundle attachment *f* were orthogonally projected onto this line and were found to lie at 36% and 52% along its length, respectively.

natural expansion of the tibial footprint can be seen some months after surgery). Placement of a graft with parallel fibers positioned too far anterior in the region where the native ligament is curved risks anterior graft impingement, loss of knee extension, and “cyclops” lesions. This is particularly pertinent to anatomic, 2-bundle reconstruction. For this reason, we chose to describe the “center” of each bundle attachment as the “parallel projection” of the central fibers of the bundle onto its attachment (rather than the geometrical median of the attachment area); we believe that this best defines where the center of the relevant tunnel should emerge into the joint.

Knowledge of the tibial attachment of the ACL and an ability to reference the position of the AM bundle from a bony landmark would therefore greatly facilitate accurate tunnel placement. Although the ACL attachment areas have been previously measured,

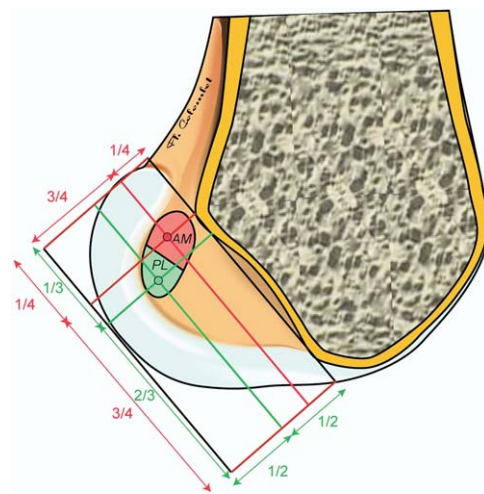


FIGURE 6. Position of the centers of the AM and PL bundles on the grid described by Bernard et al.²⁰

when recommendations were made for tunnel placement, these related to standard single-bundle reconstructions. Few data in the literature can be used to facilitate anatomic reconstruction. The objective of this study was therefore to provide quantitative data that can assist the surgeon in positioning of AM and PL bundles.

The anteroposterior diameter of the ACL attachment (**ab**) that we measured at 17.6 ± 2.1 mm was similar to that recorded by Odensten and Gillquist (17.3 mm),⁴ who also made measurements in cadavers, and by Morgan et al. (18 mm),¹⁷ who quantified the attachment in patients undergoing total knee arthroplasty. These results, however, differ from those of Girgis et al. (29.3 mm),³ who also directly measured cadaveric knees, and of Stäubli and Rauschnig (15.0 mm),²¹ who used a cadaveric frozen section technique (“cryopanning”) to quantify the tibial attachment. We found that the mediolateral diameter of the tibial attachment (**cd**) was 12.7 ± 2.8 mm. This compares with 11 mm measured by Odensten and Gillquist⁴ and 10 mm recorded by Morgan et al.¹⁷

Various anatomic reference points have also been used to define the position of the tibial attachment. The PCL has often been suggested as an intraoperative reference, with Morgan et al.¹⁷ and Jackson and Gasser¹⁸ defining the center of the tibial attachment as lying 6 to 7 mm anterior to its anterior edge. However, we believe that the PCL may be an unreliable reference in that it is a soft tissue structure rather than a fixed bony point. We preferred and used the RER—previously described by McGuire et al.²² as the “over-the-back” ridge. After they performed a retrospective analysis of 20 single-bundle ACL reconstructions with the use of computed tomography, these investigators reported that the posterior borders of their tibial tunnels lay 6.2 mm anterior to the RER (mean). This measurement corresponds to distance **bg**—the distance between the posterior border of the ACL attachment area and the RER—which we measured as 7.1 mm. Compared with the position of the center of the AM bundle (point **e**) as determined in this study—an average of 17.8 ± 1.7 mm anterior to the RER—their graft was placed posteriorly, and the position was probably more representative of the PL bundle tibial attachment. This posterior tibial tunnel may have been necessary to achieve a posterior femoral tunnel with a “cortical margin of 1 to 2 mm” via the transtibial approach, which was used.

The posterior edge of the tibia¹⁹ and the anterior border of the tibial plateau^{3,21} have also been used as bony reference points to define the position of the

ACL attachment. However, determination of the location of the tibial ACL attachment through referencing from the anterior border of the tibial plateau may be inaccurate because of the anterior slope of the tibia; both of these bony points are inaccessible during arthroscopic surgery, which would necessitate the use of fluoroscopy. In this study, the largest interobserver variations occurred for distances **hi** and **bh** on the tibia and were due to discrepancies in defining of points **i** and **h** on the anterior and posterior slopes of the tibial plateau. Referencing the position of the tibial footprint from the RER was more accurate, and we believe that use of this bony reference point could provide a reliable method of accurately determining the position of the AM bundle on the tibia. It also has the advantage of being visible during an arthroscopic intervention.

This study showed greater morphologic variation of the tibial attachments (Fig 3) than of the femoral attachments (Fig 4) between specimens. The “foot” regions of the AM and PL bundles lay mediolaterally beside each other at the tibial attachment, yet the projection of the center of the 2 bundles lay relatively more anteroposterior. This appearance was similar to that shown in previous studies²⁴ and suggests that the “foot” region of the PL bundle tends to extend more anteriorly than posteriorly and that of the AM bundle extends more posteriorly than anteriorly. Various descriptions are provided in the literature for anatomic positioning of the tunnels for 2-bundle reconstruction, particularly on the tibial side. Muneta et al.⁹ placed their AM tunnel guidewire “in the center of the ACL” attachment, with the PL wire aimed 3 mm posterior as it emerged into the joint. It is therefore unlikely that the tibial tunnels were separate as they emerged into the joint with the use of bundles that “usually measured 6 or 7 mm in diameter.” Similarly, Adachi et al.²⁵ used average sizes of 6.8 mm and 5.9 mm for PL and AM bundles, respectively, with the centers of their tunnels lying only 3 mm apart. However, others have described performing anatomic ACL reconstruction while leaving a 2-mm bony bridge between PL and AM tunnels (of average diameters of 5 and 7 mm) as they entered the joint. We found that the center of the PL bundle was located an average of 8.4 mm posterolateral to the AM bundle (distance **ef**). This suggests that with a 5-mm-diameter graft for the PL bundle and a 7-mm-diameter AM graft, it would be possible to place the centers of both grafts in their respective native attachment site positions, while leaving a 2-mm bony bridge between tunnels. This, it has been suggested, may aid healing of grafts and improve their biomechanical function.²⁶

The dimensions of the femoral attachment that we found (18×10.3 mm) were very similar to those reported by Odensten and Gillquist (18×11 mm),⁴ although Girgis et al.³ reported a length of 23 mm. We found that the size and appearance of the femoral attachment were much more consistent than those of the tibia. The position was also constant, with the attachment bordered very closely (2 to 3 mm) by the limit of the articular cartilage, proximally **I**, posteriorly **G**, and distally **H** (Table 2). The dimensions of the femoral attachment (13.9×9.3 mm) were also smaller than those of the tibial attachment (17.5×12.7 mm). This corroborates the work of Harner et al.,²⁴ who determined that the tibial attachment surface area was 120% of the femoral attachment area. Many authors^{5,6,9,27,28} have used the traditional “clock face” model to describe AM bundle positioning during anatomic ACL reconstruction (between 12:30 and 1:30), but whether this method can be used for positioning of the PL bundle is a matter of debate. Yasuda et al.²⁸ stated that the PL bundle could not be placed by the clock method because the tunnel entry point was “more distal to each point on the clock,” yet other authors have clearly defined the PL bundle position at between 1:30 and 2:30 in left knees (and between 10:30 and 9:30 in right knees).^{5,6,27} The method described by Yasuda et al.²⁸ for placing the center of the PL bundle at the intersection of 2 lines—the axis of the ACL attachment and the “V line” (a line drawn through the contact point between the femoral condyle and the tibial plateau at 90° of flexion)—might be difficult to use accurately during arthroscopic surgery. The data provided in our study suggest that a surgeon could locate the center of the PL bundle as 8 mm “lower” and “shallower” in the notch (measurement **EF** = 8.2 mm) than the center of the AM bundle (positioned by means of the clock method). This would again allow anatomic ACL reconstruction within the attachment area of the native ligament, thus maintaining an approximately 2-mm bony bridge between tunnels (using graft diameters of 7 mm for the AM bundle and 5 mm for the PL bundle).²⁶

The ability to determine tunnel positioning radiographically is also important. Often, surgeons reference the position of a tibial ACL tunnel from Blumensaat's line, but this method is inaccurate because the projection of Blumensaat's line onto the tibia is dependent on the angle of knee flexion when the radiograph is taken. We believe that determination of the position of a tibial tunnel relative to Amis and Jakob's line is more accurate because it is independent of knee flexion. When we de-

scribed the anteroposterior position of the tibial ACL attachment on a plain lateral radiograph in terms of a percentage of the length of Amis and Jakob's line, we found that the center of the AM bundle lay at 36% and the center of the PL bundle lay at 52%, with measurements taken from anterior to posterior. This compares with the work of Stäubli and Rauschning,²¹ who described the center of the entire ACL attachment and reported its center at the 43.3% position in their frozen “cryopanning” sections (44.1% in men and 43.7% in women with measurements attained from magnetic resonance images). Amis and Jakob¹³ also reported that the center of the tibial attachment lay at the 43% position. It is logical that we found a more anterior position for the center of the AM bundle and a more posterior position for the PL bundle, but bundle centers still lay well within the previously described limits of the ACL attachment relative to Amis and Jakob's line—with the anterior border at 25% and the posterior border at 62%.¹³

On the femoral side, we found that the center of the AM bundle projected onto Blumensaat's line lay at a mean of $26.4\% \pm 2.6\%$ from the most anterior part of the femoral condyle (point **J'**). This was almost identical to the $27\% \pm 4\%$ reported by Musahl et al.²⁹ in their radiographic study. This position high and deep in the notch constitutes one of the difficulties in graft placement when a double-bundle reconstruction is performed. The position of the PL bundle was $32.3\% \pm 3.9\%$ along Blumensaat's line, and the grid system proposed by Bernard et al.²⁰ could be used, together with data from this study, to verify the correct positioning of both femoral tunnels radiologically (Fig 6).

The limitations of this study were that relatively few specimens were used, although the mediolateral widths of the tibiae showed differences of 1.5 cm, demonstrating a wide range of knee sizes. The age of the specimens was also older than that of patients who were routinely undergoing ACL reconstruction; however, this was not dissimilar from previous studies.^{17,21,24} The average anteroposterior tibial diameter (55.4 mm) that we found was similar to that reported by McGuire et al.,²² who recorded the anteroposterior tibial plateau dimensions of patients after ACL reconstruction surgery. They measured 55.1 mm with the use of reconstructed computed tomography scans and 55.4 mm according to plain lateral radiographs, suggesting that our specimens provided a reasonable sample of the population.

CONCLUSIONS

This study provides new data about ACL attachments specific to anatomic, 2-bundle ACL reconstruction that may facilitate accurate tunnel placement. The radiologic locations of the centers of the AM and PL bundle attachments are given relative to Amis and Jakob's line on the tibia, and according to a grid from Bernard et al.²⁰ on the femoral side. This information could facilitate the fluoroscopic positioning of tunnels in reconstruction surgery and provide a reference for postoperative radiographic evaluation. Both cadaveric and radiologic measurements may serve as the basis for the design of instrumentation specific to the reconstruction of AM and PL bundles.

REFERENCES

- Palmer I. On the injuries to the ligaments of the knee joint. *Acta Orthop Scand Suppl* 1938;5:283.
- Brantigan OC, Voshell AF. The mechanics of the ligaments and menisci of the knee joint. *J Bone Joint Surg* 1941;23:44-66.
- Girgis FG, Marshall JL, Monajem A. The cruciate ligaments of the knee joint: Anatomical, functional and experimental analysis. *Clin Orthop* 1975;106:216-231.
- Odensten M, Gillquist J. Functional anatomy of the anterior cruciate ligament and a rationale for reconstruction. *J Bone Joint Surg Am* 1985;67:257-262.
- Franceschi JP, Sbihi A, Champsaur P. Arthroscopic reconstruction of the anterior cruciate ligament using double anteromedial and posterolateral bundles. *Rev Chir Orthop Reparatrice Appar Mot* 2002;88:691-697.
- Hamada M, Shino K, Horibe S, et al. Single- versus bi-socket anterior cruciate ligament reconstruction using autogenous multiple-stranded hamstring tendons with endoButton femoral fixation: A prospective study. *Arthroscopy* 2001;17:801-807.
- Hara K, Kubo T, Suginoshita T, Shimizu C, Hirasawa Y. Reconstruction of the anterior cruciate ligament using a double bundle. *Arthroscopy* 2000;16:860-864.
- Mae T, Shino K, Miyama T, et al. Single- versus two-femoral socket anterior cruciate ligament reconstruction technique: Biomechanical analysis using a robotic simulator. *Arthroscopy* 2001;17:708-716.
- Muneta T, Sekiya I, Yagishita K, Ogiuchi T, Yamamoto H, Shinomiya K. Two-bundle reconstruction of the anterior cruciate ligament using semitendinosus tendon with endobuttons: Operative technique and preliminary results. *Arthroscopy* 1999;15:618-624.
- Pederzini L, Adriani E, Botticella C, Tosi M. Technical note: Double tibial tunnel using quadriceps tendon in anterior cruciate ligament reconstruction. *Arthroscopy* 2000;16:E9.
- Takeuchi R, Saito T, Mitohashi S, Suzuki E, Yamada I, Koshino T. Double-bundle anatomic anterior cruciate ligament reconstruction using bone-hamstring-bone composite graft. *Arthroscopy* 2002;18:550-555.
- Amis AA, Dawkins PC. Functional anatomy of the anterior cruciate ligament. *J Bone Joint Surg Br* 1991;73:260-267.
- Amis AA, Jakob RP. Anterior cruciate ligament graft positioning, tensioning and twisting. *Knee Surg Sports Traumatol Arthrosc* 1998;6:S2-S12(suppl 1).
- Livesay GA, Fujie H, Kashiwaguchi S, Morrow DA, Fu FH, Woo SL. Determination of the in situ forces and force distribution within the human anterior cruciate ligament. *Ann Biomed Eng* 1995;23:467-474.
- Rudy T, Livesay GA, Xerogeanes JW, Takeda Y, Fu FH, Woo SL. A combined robotics/force-moment sensor approach to measure knee kinematics and determine in-situ ACL forces. *ASME Adv Bioeng BED* 1994;28:287-288.
- Boisgard S, Levai JP, Geiger B, Saidane K, Landjerit B. Study of the variations in length of the anterior cruciate ligament during flexion of the knee: Use of a 3D model reconstructed from MRI sections. *Surg Radiol Anat* 1999;21:313-317.
- Morgan CD, Kalman VR, Grawl DM. Definitive landmarks for reproducible tibial tunnel placement in anterior cruciate ligament reconstruction. *Arthroscopy* 1995;11:275-288.
- Jackson DW, Gasser SI. Tibial tunnel placement in ACL reconstruction. *Arthroscopy* 1994;10:124-131.
- Hutchinson MR, Bae TS. Reproducibility of anatomic tibial landmarks for anterior cruciate ligament reconstructions. *Am J Sports Med* 2001;29:777-780.
- Bernard M, Hertel P, Hornung H, Cierpinski T. Femoral insertion of the ACL: Radiographic quadrant method. *Am J Knee Surg* 1997;10:14-21.
- Staubli HU, Rauschnig W. Tibial attachment area of the anterior cruciate ligament in the extended knee position: Anatomy and cryosections in vitro complemented by magnetic resonance arthrography in vivo. *Knee Surg Sports Traumatol Arthrosc* 1994;2:138-146.
- McGuire DA, Hendricks SD, Sanders HM. The relationship between anterior cruciate ligament reconstruction tibial tunnel location and the anterior aspect of the posterior cruciate ligament insertion. *Arthroscopy* 1997;13:465-473.
- Petersen W, Tillmann B. Structure and vascularization of the cruciate ligaments of the human knee joint. *Anat Embryol (Berl)* 1999;200:325-334.
- Harner CD, Baek GH, Vogrin TM, et al. Quantitative analysis of human cruciate ligament insertions. *Arthroscopy* 1999;15:741-749.
- Adachi N, Ochi M, Uchio Y, Iwasa J, Kuriwaka M, Ito Y. Reconstruction of the anterior cruciate ligament: Single- versus double-bundle multistranded hamstring tendons. *J Bone Joint Surg Br* 2004;86:515-520.
- Colombet P, Robinson J, Jambou S, Allard M, Bousquet V, de Lavigne C. Two-bundle, four-tunnel anterior cruciate ligament reconstruction. *Knee Surg Sports Traumatol Arthrosc* 2005;9:1-8. Online first [Epub ahead of print].
- Bellier G, Christel P, Colombet P, Djian P, Franceschi JP, Sbihi A. Double-stranded hamstring graft for anterior cruciate ligament reconstruction. *Arthroscopy* 2004;20:890-894.
- Yasuda K, Kondo E, Ichiyama H, et al. Anatomic reconstruction of the anteromedial and posterolateral bundles of the anterior cruciate ligament using hamstring tendon grafts. *Arthroscopy* 2004;20:1015-1025.
- Musahl V, Burkart A, Debski RE, Van Scyoc A, Fu FH, Woo SL. Anterior cruciate ligament tunnel placement: Comparison of insertion site anatomy with the guidelines of a computer-assisted surgical system. *Arthroscopy* 2003;19:154-160.